



Net Images

# Terra firma-forme dermatosis

Piyush Yadav<sup>1</sup>, Sushantika Sushantika<sup>1</sup>, Kartik Saini<sup>1</sup>, Soumya Nanda<sup>1</sup>

<sup>1</sup>Department of Dermatology, Venereology and Leprosy, All India Institute of Medical Sciences, Rishikesh, Uttarakhand, India.

**\*Corresponding author:**

Piyush Yadav,  
Department of Dermatology,  
Venereology and Leprosy,  
All India Institute of  
Medical Sciences, Rishikesh,  
Uttarakhand, India.  
[piyushyadavpy227314@gmail.com](mailto:piyushyadavpy227314@gmail.com)

Received: 09 December 2024  
Accepted: 10 January 2025  
Epub Ahead of Print: 25 February 2025  
Published:

DOI  
10.25259/JSSTD\_84\_2024

Quick Response Code:



## ABSTRACT

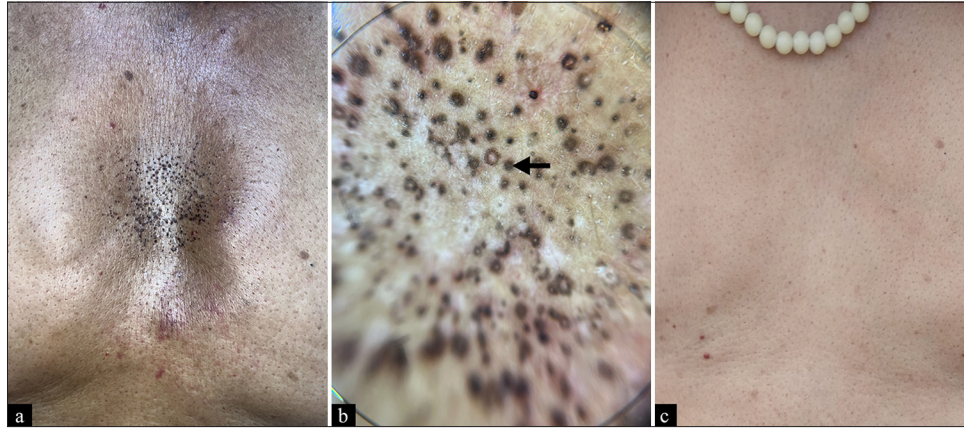
Terra firma-forme dermatosis was first described by Duncan in 1987, who observed similar cases of “dirty-appearing skin” in several children and young adults. It is an acquired, idiopathic, cutaneous pigmentation disorder characterized by brown-gray, velvety, pigmented patches or plaques involving the face, neck, trunk, or ankles. Although the exact pathogenesis is not known, it is hypothesized to be the result of abnormal and delayed keratinization, causing compaction of scales with melanin retention. Herein, we report a case of an adult male presenting with dirty-looking lesions on the chest in which the diagnosis was confirmed by wiping of the affected area using 70% isopropyl alcohol or ethyl alcohol, which was also curative.

**Keywords:** Dermatitis neglecta, Dermoscopy, Duncan’s dirty dermatosis, Pigmentation disorder, Terra firma-forme dermatosis

A 73-year-old man presented to the dermatology clinic with a 10-day history of blackish lesions on his chest. The patient had no history of atopy and reported regular bathing habits. Physical examination revealed multiple blackish papules on the chest [Figure 1a]. On close-up inspection, some lesions were annular in shape. A dermoscopy of the lesions showed brown to blackish perifollicular hyperpigmentation with sparing skin creases [Figure 1b]. The lesions did not disappear after washing with water; however, forceful rubbing with a gauze pad soaked in 70% isopropyl alcohol resulted in the complete clearance of the lesions [Figure 1c]. With confluent and reticulated papillomatosis, pityriasis versicolor, porokeratosis, and dermatitis neglecta as differential diagnoses, a final diagnosis of terra firma-forme dermatosis was made. Terra firma-forme dermatosis is differentiated from dermatitis neglecta by the presence of adequate hygiene in the patient and successful clearance of the lesion with 70% isopropyl alcohol. Also known as Duncan’s dirty dermatosis, it is a cutaneous pigmentation disorder characterized by brown-gray, pigmented patches or plaques, commonly affecting the face, neck, trunk, and ankles. It is hypothesized to result from delayed maturation of keratinocytes, leading to retention of keratinocytes and melanin within the epidermis. Dermoscopic patterns seen in Terra firma-forme dermatosis includes polygonal brown clods, seborrheic keratosis-like, and perifollicular hyperpigmentation.<sup>[1]</sup> Although not usually performed, a skin biopsy would reveal melanin retention and alterations in keratinization.<sup>[2]</sup> During a telephonic follow-up two months later, the patient reported that the lesions had not recurred. It is important to convey the patient regarding the benign nature of the dirty pigmentation to the patient as it is generally considered a cosmetic concern.

This is an open-access article distributed under the terms of the Creative Commons Attribution-Non Commercial-Share Alike 4.0 License, which allows others to remix, transform, and build upon the work non-commercially, as long as the author is credited and the new creations are licensed under the identical terms.

©2025 Published by Scientific Scholar on behalf of Journal of Skin and Sexually Transmitted Diseases



**Figure 1** (a): Physical examination showing multiple blackish, barely elevated papules on the chest, with few annular shaped lesions; (b): Dermoscopy of the lesions showing brown to blackish perifollicular hyperpigmentation (arrow) with sparing of skin creases (DermLite DL200 hybrid, polarized light,  $\times 10$ ); (c): Forceful rubbing with a gauze pad soaked in 70% isopropyl alcohol resulting in the complete clearance of the lesions.

**Ethical approval:** The Institutional Review Board approval is not required.

**Declaration of patient consent:** The authors certify that they have obtained all appropriate patient consent.

**Financial support and sponsorship:** Nil.

**Conflicts of interest:** There are no conflicts of interest.

**Use of artificial intelligence (AI)-assisted technology for manuscript preparation:** The authors confirm that there was no use of artificial intelligence (AI)-assisted technology for assisting in the writing or editing of the manuscript and no images were manipulated using AI.

## REFERENCE

1. Elmas ÖF, Uyar B, Kilitçi A, Kutlu Ö. Dermoscopic patterns of terra firma-forme dermatosis. *Dermatol Online J* 2020;26:15.
2. Mohta A, Sarkar R, Narayan RV, Deoghare S, Arora A. Terra firma-forme dermatosis-more than just dirty. *Indian Dermatol Online J* 2023;15:99-104.

**How to cite this article:** Yadav P, Sushantika S, Saini K, Nanda S. Terra firma-forme dermatosis. *J Skin Sex Transm Dis*. doi: 10.25259/JSSTD\_84\_2024