

Net Image

# Giant seborrheic keratosis on the external auditory meatus

Pradeep S. Nair<sup>1</sup>

<sup>1</sup>Department of Dermatology and Venereology, Government Medical College, Thiruvananthapuram, Kerala, India.

**\*Corresponding author:**

Pradeep S. Nair,  
Department of Dermatology  
and Venereology,  
Government Medical College,  
Thiruvananthapuram, Kerala,  
India.

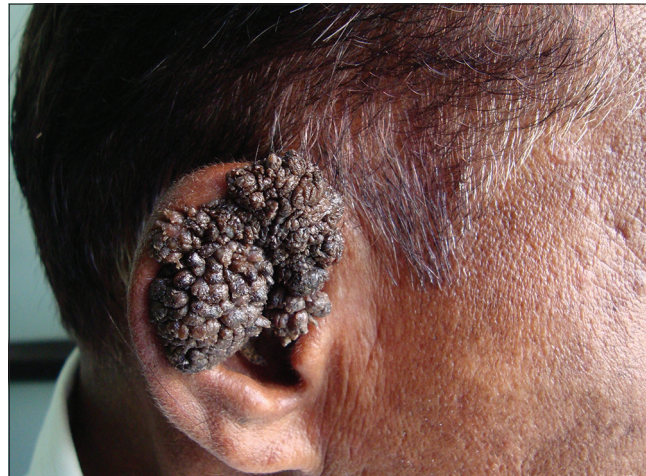dvmchtvm@yahoo.co.in

A 57-year-old-man presented with a hyperpigmented lesion on the right external auditory meatus of 9 months duration. The lesion first started on the external auditory meatus as a small, pigmented papule and then grew in size over a period of months. The lesion was asymptomatic. On examination, there was a well-defined, hyperpigmented plaque with a cerebriform surface and stuck on appearance, extending from the external auditory meatus to the helix of the right ear [Figure 1]. The plastic surgeons did an excision biopsy, which showed hyperkeratosis, keratotic plugging, massive irregular acanthosis, and horn cysts in the epidermis, diagnostic of seborrheic

Received: 26 February 2023  
Accepted: 02 April 2023  
Epub Ahead of Print: 22 May 2023  
Published: 31 December 2024

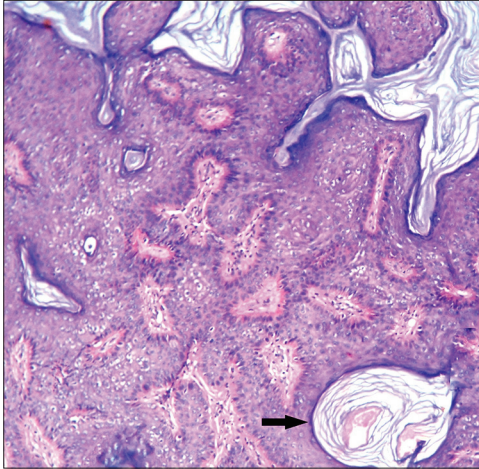
DOI  
10.25259/JSSTD\_11\_2023

Quick Response Code:



**Figure 1:** Hyperpigmented plaque with a cerebriform surface and stuck on appearance on the right ear.

This is an open-access article distributed under the terms of the Creative Commons Attribution-Non Commercial-Share Alike 4.0 License, which allows others to remix, transform, and build upon the work non-commercially, as long as the author is credited and the new creations are licensed under the identical terms.  
©2024 Published by Scientific Scholar on behalf of Journal of Skin and Sexually Transmitted Diseases



**Figure 2:** Skin biopsy showing hyperkeratosis, keratotic plugging, and irregular acanthosis. Arrow denotes horn cyst (Hematoxylin & eosin,  $\times 400$ ).

keratosis [Figure 2]. There were no histological features of any malignancy. There was no recurrence after excision.

#### **Ethical approval**

The Institutional Review Board approval is not required.

#### **Declaration of patient consent**

The authors certify that they have obtained all appropriate patient consent.

#### **Financial support and sponsorship**

Nil.

#### **Conflicts of interest**

Dr. Pradeep S. Nair is on the editorial board of the Journal.

#### **Use of artificial intelligence (AI)-assisted technology for manuscript preparation**

The authors confirm that there was no use of artificial intelligence (AI)-assisted technology for assisting in the writing or editing of the manuscript and no images were manipulated using AI.

**How to cite this article:** Nair PS. Giant seborrheic keratosis on the external auditory meatus. *J Skin Sex Transm Dis.* 2024;6:225-6. doi:10.25259/JSSD\_11\_2023.