



Net Educational Video for Residents

Dark ground microscopy for identification of *Treponema pallidum*

Betsy Ambooken¹, Vayappurath G Binesh¹, Neelakandhan Asokan¹, Abdulsalam Sarin¹, Balaguru Natarajan², Cheruvathoor Thankachan Subi¹

¹Department of Dermatology and Venereology, Government Medical College, Thrissur, Kerala, ²Department of Dermatology, Venereology and Leprosy, Arunai Medical College, Tiruvanamalai, Tamil Nadu, India.

*Corresponding author:

Betsy Ambooken,
Department of Dermatology
and Venereology, Government
Medical College, Thrissur,
Kerala, India.

joebetsy123@gmail.com

Received: 24 July 2022
Accepted: 10 August 2022
Epub Ahead of Print: 03 September 2022
Published: 31 December 2024

DOI
10.25259/JSSTD_39_2022

Videos available online at:
https://doi.org/10.25259/JSSTD_39_2022

Quick Response Code:



ABSTRACT

Demonstration of *Treponema pallidum* under the dark ground microscope is a rapid onsite method for diagnosis in early syphilis. The steps involve obtaining patient consent, specimen collection from an infective lesion of early syphilis, the adjustments of dark field microscope, and identification of treponemes by virtue of their characteristic morphology and motility.

Keywords: Dark field microscopy, *Treponema pallidum*, Syphilis

INTRODUCTION

Dark ground microscopy or dark field microscopy (DFM) is a rapid onsite method for identification of *Treponema pallidum*, particularly in the early phase of primary syphilis, where serological tests can be negative.^[1,2] Although there are more specific and sophisticated methods for diagnosis of syphilis, dark field microscope is still an essential equipment in tertiary care centers with sexually transmitted infection clinics as it offers rapid, cheap and highly reliable diagnosis of early syphilis.

T. pallidum is a thin spiral organism with a characteristic motility and measures 6–15 microns in length and 0.25 microns in width.^[3,4] In cases of primary syphilis, demonstration of treponemes by DFM had a sensitivity of 75–100% and a specificity of 94–100% when compared with diagnosis by clinical presentation and laboratory findings (serology and/or nucleic acid amplification test).^[5] In secondary syphilitic lesions, the sensitivity was 58–71% and specificity was 100%.^[5]

Principle of dark field microscope

Dark field microscope is a modification of light microscope with a built-in dark field condenser which has an opaque stop or disc. It also has an oil immersion objective with a funnel stop that helps to reduce its aperture.^[3,4] An ordinary microscope can be used for DFM by replacing the Abbe condenser with the dark ground condenser and the 2 mm oil immersion objective should have a built in adjustable diaphragm to reduce the aperture size to 0.95.^[3] The opaque stop of the dark field condenser blocks the direct light rays and permits only oblique light to pass through. This light gets reflected through the specimen in the glass slide to reach the objective lens [Video 1]. Thus a dark background is created, in which unstained cells and organisms are seen as bright objects.

This is an open-access article distributed under the terms of the Creative Commons Attribution-Non Commercial-Share Alike 4.0 License, which allows others to remix, transform, and build upon the work non-commercially, as long as the author is credited and the new creations are licensed under the identical terms.
©2024 Published by Scientific Scholar on behalf of Journal of Skin and Sexually Transmitted Diseases

INDICATIONS

1. Primary syphilis: Specimen is best obtained from clear serum exuding from a primary chancre. Aspirate from enlarged regional lymph nodes may be taken, if the primary chancre is healed or if it is not visible due to phimosis.^[6]
2. Secondary syphilis: Specimen may be taken from a moist lesion such as condylomata lata [Figure 1] or serum obtained on scarifying the dry skin lesions.^[3]
3. Congenital syphilis: Specimen may be taken from moist or bullous lesions in the early stage of congenital syphilis.

PROCEDURE

The four main steps include patient consent, specimen collection, adjustments of DFM, and identification of *T. pallidum* [Video 2].

The procedure should be explained to the patient and appropriate consent should be taken. The patient should be sitting or lying in a comfortable position. Universal safety precautions should be followed.

It is advisable to keep the dark field microscope ready, before obtaining the specimen as treponemes lose motility with passage of time.^[5]

A tray is set with clean cover slip, glass slide, blotting paper, sterile swab, drape, saline, and sterile surgical gloves. A bottle with immersion oil with applicator is also kept ready.

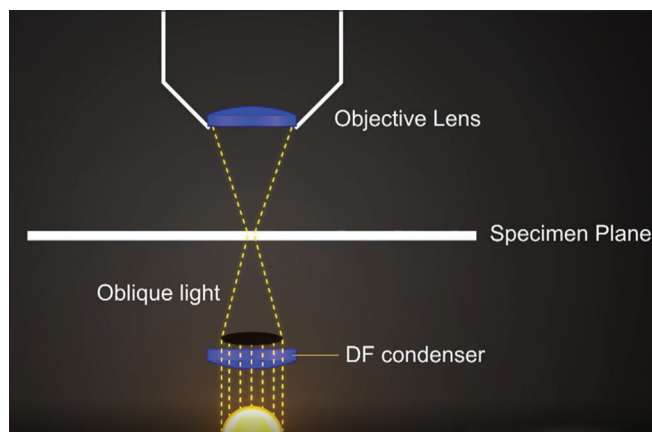
Two sterile surgical gloves are worn as the outer glove needs to be discarded after specimen collection.

Specimen collection

The swab is soaked with saline and the surface of the lesion is cleansed thoroughly and mopped dry. The sore is squeezed between the thumb and the index finger of the left hand to allow adequate flow of clear serum (free of red blood cells).^[6] The cover-slip is taken in the right hand and is applied to the surface of the wet lesion so that a drop of serum adheres to it. The cover slip with serum on its under surface is immediately placed on the glass slide and pressed firmly with a piece of blotting paper. Do not dilute the serum even if the quantity is small.^[3] The outer glove is now discarded.

Dark ground microscope adjustments

The light source of the microscope is switched on and adjusted to its maximum. The dark field condenser is raised and a drop of oil is placed on top of the condenser. Place a drop of oil on the cover slip and another on the under surface of the glass slide with the specimen. The glass slide is placed in such a way that the two drops of oil coalesce without entrapping any air bubbles.^[3,6] Now focus (initially with 10× lens) till the field is evenly illuminated and maximum contrast



Video 1: Principle of dark field microscope.

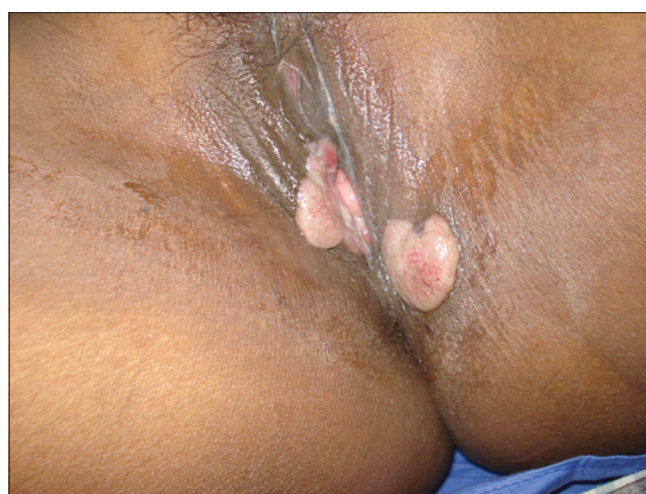


Figure 1: Fleshy, moist lesions of condylomata lata.

is obtained. Then, oil immersion objective (100×) is changed to DF mode to reduce the aperture size. The oil immersion/DF objective is racked down until it makes contact with the oil. The contents of serum are visualized as white objects on a dark background. Treponemes are identified by virtue of their morphology and characteristic motility. Discard all used instruments and materials into the appropriate containers.^[7]

If specimen is to be obtained from a lymph node, 0.1 ml of sterile saline is first injected into the enlarged lymph node with the right hand and with the left hand, massage the node, and then aspirate.^[3,6] The material thus obtained is immediately examined under DFM as above.

Identification of *T. pallidum*

T. pallidum is identified under DFM as white, glistening, spiral-shaped organism [Video 2] with characteristic corkscrew rotatory movements together with movements of change of shape such as angulation, buckling, undulation, looping, coil compression, and expansion.^[1-3]



Video 2: Procedure of specimen collection, dark ground microscope adjustments, and identification of *Treponema pallidum*.

INTERPRETATION OF RESULTS

A well trained and experienced personnel is required for demonstration and identification of treponemes under dark field microscope. The specimen should be examined immediately (within 20 minutes) as treponemes lose motility with passage of time.^[5] Application of antiseptics or antibiotic ointments over the lesion would reduce the chance of demonstrating *T. pallidum*.

Sensitivity will be less, if the lesion is dry or healing. In such cases, the edge of the lesion, where more number of treponemes are likely to be present, may be scarified gently with a scalpel, to obtain the specimen.^[3]

Blood or pus from the lesion should be meticulously removed before specimen collection, as these may interfere with the demonstration of *T. pallidum*. Specimens from oral or rectal mucosa are best avoided or interpreted with caution as false positive results may be obtained due to the presence of saprophytic treponemes like *Treponema microdentium*. It is difficult to differentiate non-venereal treponemes causing pinta, yaws or bejel from those causing syphilis. More specific tests like direct fluorescent antibody staining for *T. pallidum* using fluorescent microscopy or polymerase chain reaction may be needed coupled with clinical correlation.^[1-6]

False-negative results on DFM

If the number of organisms present in the specimen is insufficient or if the patient has already been started on treatment for syphilis; or a topical antibacterial preparation has been applied to the lesion; or the lesion is approaching natural resolution, DFM may give negative result for *T. pallidum*.

If during the first visit no treponemes are visualized, the procedure should be repeated daily for 3 consecutive days, especially if clinical suspicion is high.^[6]

CONCLUSION

DFM is a rapid and relatively cheap onsite method for identification of treponemes especially in the hands of

experienced personnel. In view of the rising incidence of primary and secondary syphilis, more emphasis should be placed on learning and performing DFM for early diagnosis of syphilis, especially in settings with limited access to more costly tests.

Ethical approval

The Institutional Review Board approval is not required.

Declaration of patient consent

The authors certify that they have obtained all appropriate patient consent.

Financial support and sponsorship

Nil.

Conflicts of interest

Dr. Betsy Ambooken, Dr. Neelakandhan Asokan, and Dr. Abdulsalam Sarin are on the editorial board of the Journal.

Use of artificial intelligence (AI)-assisted technology for manuscript preparation

The authors confirm that there was no use of artificial intelligence (AI)-assisted technology for assisting in the writing or editing of the manuscript and no images were manipulated using AI.

REFERENCES

1. Luo Y, Xie Y, Xiao Y. Laboratory diagnostic tools for syphilis: Current status and future prospects. *Front Cell Infect Microbiol* 2021;10:574806.
2. Wheeler HL, Agarwal S, Goh BT. Dark ground microscopy and treponemal serological tests in the diagnosis of early syphilis. *Sex Transm Infect* 2004;80:411-4.
3. King A, Nicol C. *Venereal Diseases*. 3rd ed. London: William and Wilkins; 1975. p. 344-6.
4. Mehta V, Saurav K, Balachandran C. Dark ground microscopy. *Indian J Sex Transm Dis* 2008;29:105-6.
5. Theel ES, Katz SS, Pillay A. Molecular and direct detection tests for treponema pallidum subspecies pallidum: A review of the literature 1964-2017. *Clin Infect Dis* 2020;71 Suppl 1:S4-12.
6. Willcox RR, Wilcox JR. *Pocket Consultant of Venereological Medicine*. Bombay: Oxford University Press; 1992. p. 168-9.
7. Available from: https://www.cpcb.nic.in/uploads/projects/bio-medical-waste/guidelines_healthcare [Last accessed on 2018 Jun].

How to cite this article: Ambooken B, Binesh VG, Asokan N, Sarin A, Natarajan B, Subi CT. Dark ground microscopy for identification of *Treponema pallidum*. *J Skin Sex Transm Dis*. 2024;6:185-7. doi: 10.25259/JSSTD_39_2022.