



Net Letter

Bilateral nevoid hyperkeratosis of nipple and areola: A rare entity

Pradeep S. Nair¹, Anju Treesa¹, Athira Sudheesan¹

¹Department of Dermatology and Venereology, Government Medical College, Thiruvananthapuram, Kerala, India.

***Corresponding author:**

Pradeep S. Nair,
Department of Dermatology
and Venereology,
Government Medical College,
Thiruvananthapuram, Kerala,
India.

dvchtvm@yahoo.co.in

Received: 01 July 2023
Accepted: 23 July 2023
Epub Ahead of Print: 17 August 2022
Published: 31 December 2024

DOI
10.25259/JSSTD_37_2023

Quick Response Code:



Dear Editor,

Nevoid hyperkeratosis of the nipple and areola (NHNA) is a rare, benign disorder affecting the nipples and areola. Most of the affected are young women.^[1]

A 21-year-old non-pregnant woman presented with enlargement and increased pigmentation of both nipples and areola (more on the left side) of 5 years duration. The lesions initially started as hyperpigmented papules on the left nipple and areola and subsequently involved the right nipple and areola. The lesions were asymptomatic and there was no discharge from the nipples. She did not give a history of any comorbidities such as thyroid disorders, diabetes mellitus, and polycystic ovarian disease. She denied any recent weight gain.

Clinical examination revealed multiple, well-defined, discrete and confluent hyperpigmented, hyperkeratotic, and verrucous papules and plaques on the nipples and areola of both breasts [Figure 1a], more prominent on the left side, where the nipple was obscured [Figure 1b]. There was no discharge from the nipples. Breast examination did not reveal any mass lesion. The axillary lymph nodes were not enlarged.

Similar lesions were not seen in any other body site. Systemic examination was unremarkable.

Dermoscopy showed a central area of hyperkeratosis, yellowish-brown areas, and homogenous brown areas [Figure 2]. Skin biopsy showed keratotic plugging, irregular filiform acanthosis, and increased pigmentation of the basal layer [Figure 3]. Mammogram and ultrasound study of the breast did not reveal any pathology. The clinical, dermoscopy, and histopathology findings were diagnostic of NHNA. The patient was referred to the plastic surgery department, where she underwent excision of the lesions and reconstruction of the nipples.

NHNA is a benign rare condition of unknown etiology. The lesions remain asymptomatic and treatment is offered for the cosmetic concern. However, the involvement of the nipples may lead to feeding difficulties in lactating mothers.

The condition is mostly seen in women. Puberty and pregnancy are identified as precipitating factors. Hence, an underlying role for hormones (estrogen) has been proposed.^[1] There have been reports of drug-induced NHNA and the precipitating drugs were spironolactone and vemurafenib.^[2]

Viral deoxyribonucleic acid has not been demonstrated in the lesions. The lesions can be unilateral or symmetric (as in our case).^[1] NHNA can be primary (idiopathic) or secondary.^[3] In

This is an open-access article distributed under the terms of the Creative Commons Attribution-Non Commercial-Share Alike 4.0 License, which allows others to remix, transform, and build upon the work non-commercially, as long as the author is credited and the new creations are licensed under the identical terms.

©2024 Published by Scientific Scholar on behalf of Journal of Skin and Sexually Transmitted Diseases

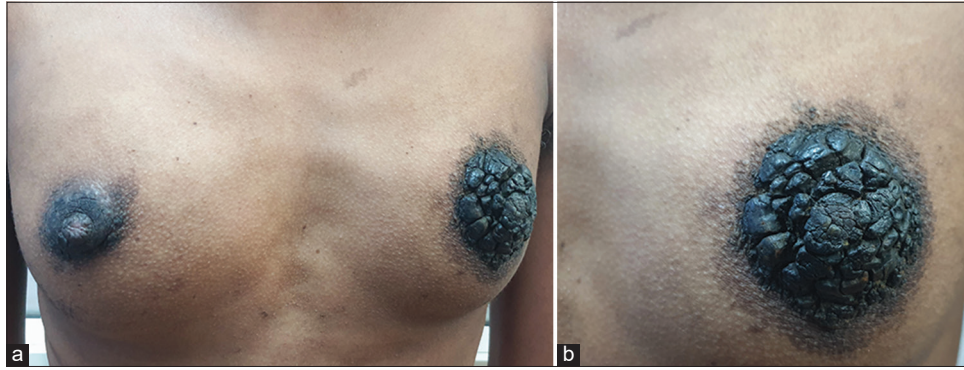


Figure 1 (a): Hyperpigmented, hyperkeratotic, verrucous papules, and plaques on the nipple and areola in a woman with nevoid hyperkeratosis of nipple and areola; (b): close-up view of the same showing the lesion obscuring the left nipple.




Figure 2: Dermoscopy of nevoid hyperkeratosis of nipple and areola showing central white hyperkeratosis (straight arrow), yellowish-brown areas (up arrow), and homogenous brown areas (down arrow) (DermLite, non-polarized light, $\times 10$).

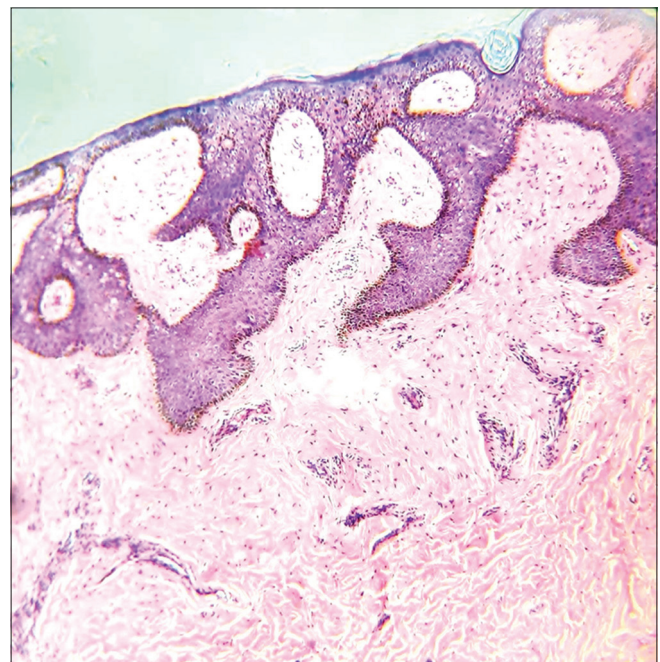


Figure 3: Skin biopsy showing keratotic plugging, filiform, irregular acanthosis, and increased pigmentation of basal layer (Hematoxylin & eosin, $\times 400$).

secondary NHNA, the lesions are caused by other dermatoses such as epidermal nevus, verrucae, or seborrheic keratosis.^[3]

Our patient manifested the primary type since the histopathology did not show features of any other dermatosis. There are no histopathological features specific to NHNA; however, filiform, irregular acanthosis with increased basal cell pigmentation is recognized as a common finding (as observed in our patient).^[4]

The important clinical and histopathological differential diagnoses include acanthosis nigricans, seborrheic keratosis, and epidermal nevus. Acanthosis nigricans classically affects the nape of the neck, and flexures and not the nipples. The histopathology shows normal basal pigmentation and no acanthosis, unlike NHNA. Seborrheic keratosis

shows discrete papules with a stuck-on appearance and histopathology is characterized by horn cysts, pseudohorn cysts, papillomatosis of the epidermis, and discrete fibrosis of the upper dermis. Epidermal nevus presents at birth or soon after birth and histopathology shows epidermal hyperplasia with papillomatosis and epidermolytic hyperkeratosis. NHNA is diagnosed based on a combination of clinical and histopathological features.^[5] Dermoscopy may also aid in diagnosis. The dermoscopy findings noted in NHNA include a papillomatous surface with pink homogenous areas, whitish desquamation, red dots, and erosions, homogeneous brown network, hyperkeratotic areas, and yellow-brown scales.^[6,7] However, dermoscopic findings are non-specific and only aid to support clinical and histopathological diagnosis.

There are no definite treatment modalities for NHNA, but surgical excision with reconstruction is the best option, which was done in our patient. Other therapeutic modalities include topical preparations such as salicylic acid and lactic acid, 0.05% tretinoin, calcipotriol, and hydroquinone.^[6] Systemic retinoids were not found effective. Liquid nitrogen cryotherapy and carbon dioxide ablative laser therapy have been tried with mixed results.^[6]

Ethical approval

The Institutional Review Board approval is not required.

Declaration of patient consent

The authors certify that they have obtained all appropriate patient consent.

Financial support and sponsorship

Nil.

Conflicts of interest

Dr. Pradeep Nair is on the editorial board of the Journal.

Use of artificial intelligence (AI)-assisted technology for manuscript preparation

The authors confirm that there was no use of artificial intelligence (AI)-assisted technology for assisting in the

writing or editing of the manuscript and no images were manipulated using AI.

REFERENCES

1. Muñoz-Aceituno E, Colmenero I, González-Meli B, Torrelo A, Hernández-Martín Á. Focal nevoid hyperkeratosis of the nipple in a prepubertal girl. *Pediatr Dermatol* 2019;36:247-8.
2. Carr ES, Brown SC, Fiala KH. Painful nipple hyperkeratosis secondary to vemurafenib. *Dermatol Ther* 2017;30:79-81.
3. Wang MF, Wang L, Li LF. Bilateral hyperkeratosis of the nipples and areolae with linear nevus: A rare case report and review of the literature. *Postgrad Med* 2018;130:361-4.
4. Succaria F, Rosenbaum M, Goldberg LJ, Mahalingam M. Dark brown plaques and patches on the breast and areola in a 14-year-old female. Nevoid hyperkeratosis of the areola and breast. *Am J Dermatopathol* 2015;37:621-2.
5. Mazzella C, Costa C, Fabbrocini G, Marangi GF, Russo D, Merolla F, *et al.* Nevoid hyperkeratosis of the nipple mimicking a pigmented basal cell carcinoma. *JAAD Case Rep* 2016;2:500-1.
6. Cinotti E, Provvidenziale L, Miracco C, Rubegni P. Treatment of nevoid hyperkeratosis of the areola and nipple with topical tacalcitol: A case report. *Dermatol Ther* 2018;31:e12602.
7. Conforti C, Dri A, Giuffrida R, Zalaudek I, di Meo N. Dermoscopic features of nevoid hyperkeratosis of the nipple and areola. *Dermatol Pract Concept* 2022;12:e2022003.

How to cite this article: Nair PS, Treasa A, Sudheesan A. Bilateral nevoid hyperkeratosis of nipple and areola: A rare entity. *J Skin Sex Transm Dis.* 2024;6:204-6. doi: 10.25259/JSSSTD_37_2023.