

Net Image

Giant seborrheic keratosis on the external auditory meatus

Pradeep S. Nair¹

¹Department of Dermatology and Venereology, Government Medical College, Thiruvananthapuram, Kerala, India.

***Corresponding author:**

Pradeep S. Nair,
Department of Dermatology
and Venereology,
Government Medical College,
Thiruvananthapuram, Kerala,
India.

dvmchtvm@yahoo.co.in

A 57-year-old-man presented with a hyperpigmented lesion on the right external auditory meatus of 9 months duration. The lesion first started on the external auditory meatus as a small, pigmented papule and then grew in size over a period of months. The lesion was asymptomatic. On examination, there was a well-defined, hyperpigmented plaque with a cerebriform surface and stuck on appearance, extending from the external auditory meatus to the helix of the right ear [Figure 1]. The plastic surgeons did an excision biopsy, which showed hyperkeratosis, keratotic plugging, massive irregular acanthosis, and horn cysts in the epidermis, diagnostic of seborrheic

Received: 26 February 2023
Accepted: 02 April 2023
Epub Ahead of Print: 22 May 2023
Published:

DOI
10.25259/JSSTD_11_2023

Quick Response Code:

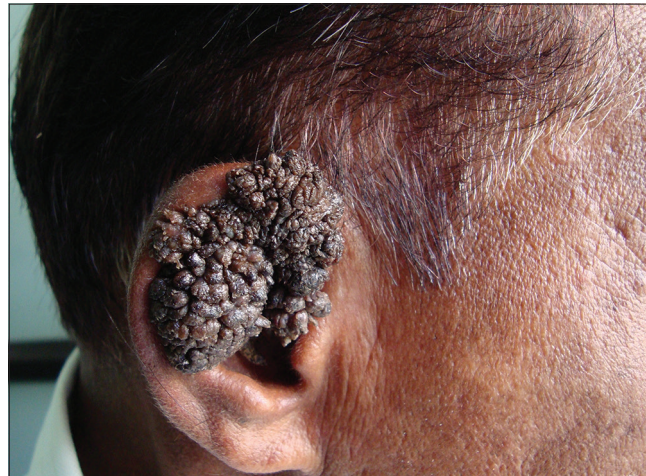

Figure 1: Hyperpigmented plaque with a cerebriform surface and stuck on appearance on the right ear.

This is an open-access article distributed under the terms of the Creative Commons Attribution-Non Commercial-Share Alike 4.0 License, which allows others to remix, transform, and build upon the work non-commercially, as long as the author is credited and the new creations are licensed under the identical terms.

©2023 Published by Scientific Scholar on behalf of Journal of Skin and Sexually Transmitted Diseases

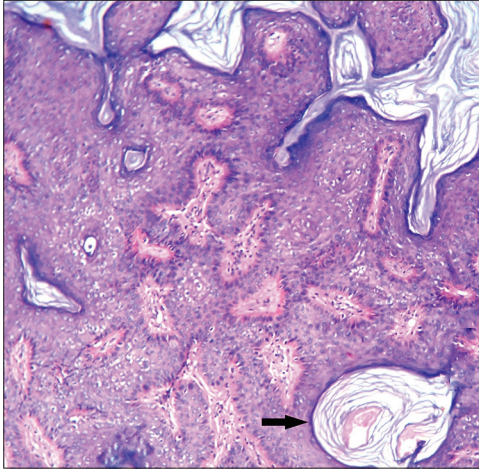


Figure 2: Skin biopsy showing hyperkeratosis, keratotic plugging, and irregular acanthosis. Arrow denotes horn cyst (H and E, $\times 400$).

keratosis [Figure 2]. There were no histological features of any malignancy. There was no recurrence after excision.

Declaration of patient consent

The authors certify that they have obtained all appropriate patient consent.

Financial support and sponsorship

Nil.

Conflicts of interest

Dr. Pradeep S. Nair is on the editorial board of the Journal.

How to cite this article: Nair PS. Giant seborrheic keratosis on the external auditory meatus. *J Skin Sex Transm Dis* doi: 10.25259/JSSD_11_2023.