



Net Quiz in Dermatology

Quiz questions from dermoscopy of infectious dermatoses (Infectiouscopy/Entodermoscopy)

Vishal Gaurav¹ , Pavani Gowda¹

¹Department of Dermatology and Venereology, Maulana Azad Medical College, New Delhi, India.

***Corresponding author:**

Vishal Gaurav,
Department of Dermatology
and Venereology, Maulana
Azad Medical College,
New Delhi, India.

mevishalgaurav@gmail.com

Received: 26 July 2024
Accepted: 01 September 2024
Epub Ahead of Print: 30 October 2024
Published:

DOI
10.25259/JSSTD_32_2024

Quick Response Code:



QUESTIONS:

- Which dermoscopic feature is typically seen in cutaneous myiasis?
 - Bird's feet-like structures
 - Yellowish structure with black spines
 - Thorn crown-like structures
 - All the above
- Dermoscopy of tungiasis shows:
 - Yellowish crusts with central black dots
 - Pearly white nodules with a central black punctum
 - Whitish homogeneous lesion with a central brown pigmented ring
 - Red papules with central ulceration
- A male patient presented with generalized itching, which worsened at night. He also reported similar symptoms in family members. On examination, multiple erythematous papules were observed in the finger web spaces and the periumbilical area. Dermoscopy findings are shown in Figure 1. What is the name of this dermoscopic sign?
 - Delta-wing jet with contrail
 - Setting sun sign
 - Little red riding hood sign
 - Jelly sign
- In cutaneous leishmaniasis, the 'white starburst-like pattern' is observed during which stage?
 - Early lesions
 - Intermediate lesions
 - Late stages
 - Healing stages
- 'Falooda seeds' appearance on dermoscopy is seen in:
 - Palmoplantar warts
 - Filiform warts
 - Genital warts
 - Verruca plana
- Figure 2 displays the ultraviolet dermoscopic image of a healthy individual's face. Which organism is responsible for the characteristic fluorescence seen in this figure?
- What is the main dermoscopic feature of cutaneous larva migrans?
 - Brownish structureless areas in a segmental arrangement

This is an open-access article distributed under the terms of the Creative Commons Attribution-Non Commercial-Share Alike 4.0 License, which allows others to remix, transform, and build upon the work non-commercially, as long as the author is credited and the new creations are licensed under the identical terms.

©2024 Published by Scientific Scholar on behalf of Journal of Skin and Sexually Transmitted Diseases

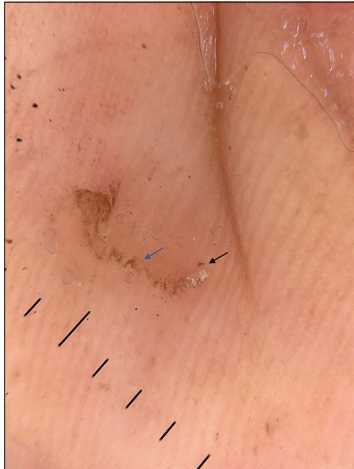


Figure 1.

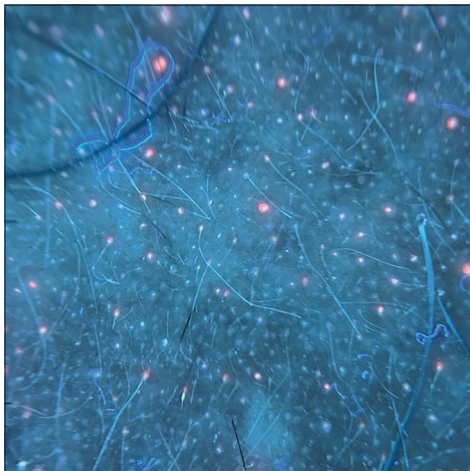

Figure 2.



Figure 3.

- b. Linear branching vessels
 - c. Central ulceration with scales
 - d. Yellowish nodules
8. Which pattern is commonly observed in the dermoscopy of molluscum contagiosum?
 - a. Blue-gray dots
 - b. Central yellowish-white polylobular amorphous structure
 - c. Brownish reticular pattern
 - d. Starburst pattern
 9. A 25-year-old male patient presented with an unpleasant odor and yellowish discoloration of hair in both axillae. Dermoscopy was performed, and the findings are depicted in Figure 3. What dermoscopic signs are observed in this condition?
 10. Which of the following is a dermoscopic feature of lupus vulgaris?
 - a. Orange to golden background pigmentation
 - b. Linear telangiectasias
 - c. White structureless areas
 - d. All the above
 11. Which of the following dermoscopic findings is indicative of white piedra?
 - a. Easily detachable white, bizarrely shaped, amorphous structures
 - b. Elongated tubular structures encircling the hair shaft and easily movable along it
 - c. Localized whitish areas along the hair shafts, resulting from fractured and frayed hair
 - d. White amorphous material locally encasing the hair
 12. A 13-year-old girl presented with severe scalp itching for the past 3 months and has a history of similar complaints in her younger sister. Dermoscopy findings are shown in Figure 4. Which structures are seen?
 13. Whitish scales along plantar creases are seen on dermoscopy of:
 - a. Plantar warts
 - b. Plantar corn
 - c. Tinea pedis
 - d. Pitted keratolysis
 14. In dermoscopy of *Demodex folliculorum*, what do whitish creamy threads suggest?
 - a. Tails
 - b. Body
 - c. Legs
 - d. Mouth parts
 15. Which trichoscopic finding has the highest predictive value for diagnosing tinea capitis?
 - a. Black dots
 - b. Broken hairs
 - c. Comma hairs
 - d. Perifollicular scaling
 16. Which trichoscopic feature is more commonly detected



Figure 4.

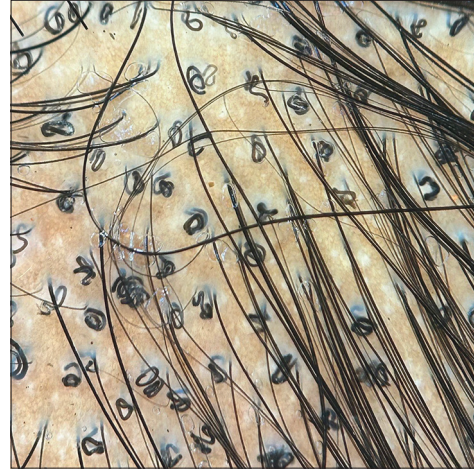


Figure 5.

in *Trichophyton tinea capitis* compared to *Microsporum tinea capitis*?

- a. Morse code-like hairs
 - b. Zigzag hairs
 - c. Bent hairs
 - d. Corkscrew hairs
17. What treatment should be recommended for a child with the dermoscopic findings depicted in Figure 5?
- a. Griseofulvin
 - b. Itraconazole
 - c. Fluconazole
 - d. Terbinafine
18. Dermoscopy of pitted keratolysis typically shows:
- a. Irregular whitish structures
 - b. Heterogeneous architecture at the periphery of the craters
 - c. Scales along ridges
 - d. Yellowish areas
19. The dermoscopic features of *Cydnidae* pigmentation are:
- a. Clusters of numerous oval to shiny brown globules and granules
 - b. Bizarre-shaped pigmented structures
 - c. Accentuated pigmentation along skin furrows and eccrine openings
 - d. All the above
20. A 56-year-old woman presented with asymptomatic discoloration of her left thumb nail for the past year. Despite treatment with oral antifungals, there was no improvement. Onychoscopy is shown in Figure 6. What is the diagnosis and the name of the dermoscopic sign depicted in Figure 6?
21. Chick-pea flour pattern is seen on onychoscopy of:
- a. White superficial onychomycosis
 - b. Endonyx
 - c. Distal lateral subungual onychomycosis

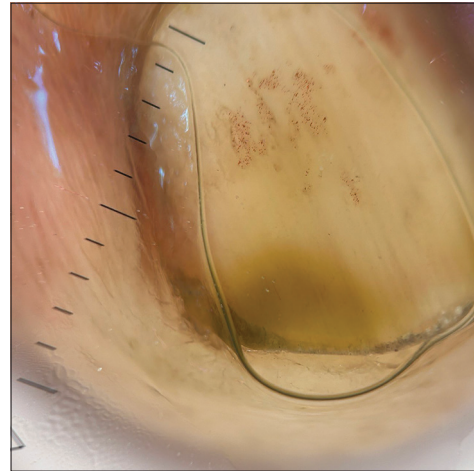


Figure 6.

- d. Proximal subungual onychomycosis
22. Which of the following onychoscopic signs has the highest sensitivity and specificity for the diagnosis of onychomycosis?
- a. Ruin appearance
 - b. Longitudinal striae
 - c. Spikes on the proximal margin of onycholytic areas
 - d. Aurora borealis sign
23. Dendritic pattern on onychoscopy is seen in:
- a. Distal lateral subungual onychomycosis
 - b. Proximal subungual onychomycosis
 - c. Superficial onychomycosis
 - d. Endonyx onychomycosis
24. Identify the onychoscopic sign shown in Figure 7 and specify the condition.
25. Which of the following findings is specific to pityriasis versicolor as identified in dermoscopic studies?
- a. White scales over a dull diffuse white or brown background

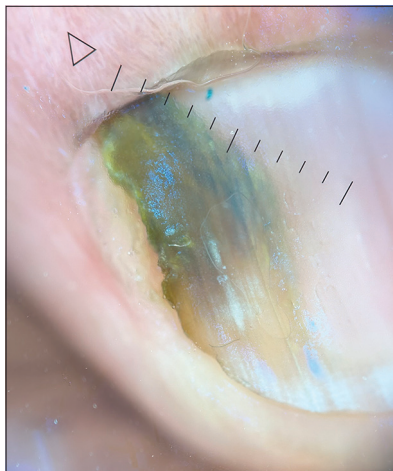


Figure 7.

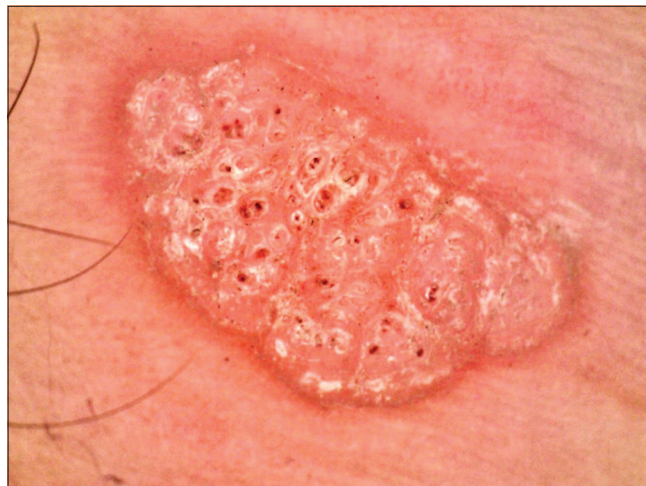

Figure 8.

- b. Folliculocentricity (perifollicular white halo)
 c. Contrast halo sign (ring of alternate pigmentation surrounding the primary lesion)
 d. All of the above
26. Which of the following dermoscopic features is commonly observed in leprosy across all its subtypes?
 a. White structureless areas
 b. Hyperpigmentation with irregular borders
 c. Yellow/yellowish-orange areas
 d. Peripheral hyperpigmentation
27. 'White jade coin pendant sign' is a dermoscopic sign of:
 a. Cutaneous histoplasmosis
 b. Chromomycosis
 c. Cutaneous talaromycosis
 d. Basidiobolomycosis
28. A 12-year-old boy presented with multiple asymptomatic, skin-colored to hyperpigmented papules on his right hand. Dermoscopic examination is shown in Figure 8. What is the diagnosis?
29. Which of the following diseases shows a 'noodle pattern' on dermoscopy?
 a. Crusted scabies
 b. Myiasis
 c. Tungiasis
 d. Phthiriasis
30. A 45-year-old female presented with acute onset painful grouped vesicular eruption of the right side of her abdomen extending to the back. Dermoscopy findings are shown in Figure 9. What is the name of this dermoscopic sign and what is the diagnosis?

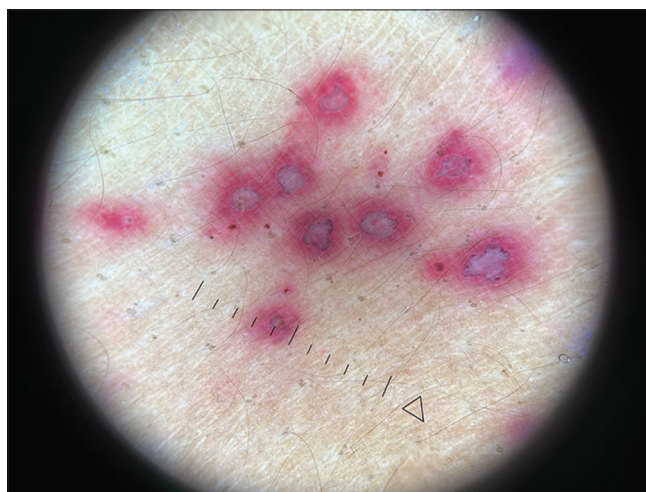


Figure 9.

- spiracles, yellowish structures with black barb-like spines extruding from the periphery, and a thorn-crown appearance due to black dots on the outer edge of the larva.^[1]
2. (c). A whitish homogeneous lesion with a central brown pigmented ring is characteristic of tungiasis, which is caused by the female sand flea (*Tunga penetrans* and *Tunga trimamillata*). The white areas correspond to the parasite's dilated abdomen containing eggs, while the central light brown structure corresponds to the posterior segment of the parasite.^[2]
3. (a). Delta-wing jet with contrail (jet with trail) sign. It represents the burrow with the mite at the end, appearing as a dark triangle (mite; black arrow) followed by a thin, wavy line (burrow; blue arrow).^[3,4]
4. (c). Dermoscopic examination of early lesions of cutaneous leishmaniasis reveals yellow tear-shaped structures and vessels, whereas late lesions display a

ANSWERS:

1. (d). Cutaneous myiasis is caused by the larval stage of different botflies. Dermoscopy of furuncular myiasis reveals bird feet-like structures corresponding to respiratory

- starburst pattern with peripheral vascular structures.^[4,5]
5. (a). Dermoscopy of palmoplantar warts reveals hemorrhagic and thrombosed black dots and globules, surrounded by a white halo, resembling wet basil seeds in falooda.
 6. Answer: *Cutibacterium acnes*. Sebaceous gland openings exhibit fluorescence under ultraviolet light, which ranges in color from bright blue/green to yellow, orange, or red. This characteristic fluorescence can be particularly useful in diagnosing and monitoring acne vulgaris. Notably, orange fluorescence is due to the presence of porphyrins produced by *C. acnes* (formerly *Propionibacterium acnes*).^[8,9]
 7. (a). Dermoscopy of cutaneous larva migrans reveals translucent, brownish, structureless areas arranged segmentally, corresponding to the body of the larva. In addition, dotted vessels representing empty burrows can also be observed.^[10]
 8. (b). Dermoscopy of molluscum contagiosum typically reveals a central white-yellowish polylobular amorphous structure, surrounded by a crown of vessels.^[11,12]
 9. Skewer sign and plume sign. Trichoscopy reveals golden-yellow, cotton-like deposits sticking to the affected hair shafts. A detailed view may show nodules and deposits with a flame-like appearance. Some hair shafts display waxy, yellowish nodules and deposits along their entire length, a feature referred to as the skewer sign. In addition, a localized pale-yellowish nodule can produce what is known as the plume sign.^[13,14]
 10. (d). Dermoscopy of lupus vulgaris reveals a yellow background pigmentation with linear telangiectasias, which corresponds to the clinically observed apple jelly sign. This sign can also be seen in other granulomatous conditions. Lupus vulgaris additionally presents with white structureless areas, follicular plugs, yellow-white scales, dilated follicles, and erythema.^[4,15]
 11. (d). White piedra presents as white amorphous material locally encasing the hair. Dermoscopy of seborrheic dermatitis reveals easily detachable white, bizarrely shaped, amorphous structures. Elongated tubular structures that encircle the hair shaft and are easily movable along it, known as hair casts, can be seen in traction alopecia, folliculitis decalvans or idiopathically. Trichobacteriosis is identified by waxy and yellowish/whitish adherent aggregates forming a sheath around the axillary hair shaft. Trichorrhexis nodosa is characterized by localized whitish areas along the hair shafts, resulting from fractured and frayed hair.^[13,14,16]
 12. *In vivo* dermoscopy can identify three stages of nits: active viable nits are ovoid, whitish-brown structures containing eggs or viable embryos, located close to the scalp; abortive nits are translucent with a condensed non-viable embryo and a dehiscing operculum, found about 5 mm or farther from the scalp; and empty nits are translucent whitish crystalline structures without an operculum, typically more than 1 cm away from the scalp.^[4,17]
 13. (c). Dermoscopy of tinea pedis and manuum shows whitish scales along creases and brownish scales corresponding to dried vesicles.^[18]
 14. (a). Dermoscopy of demodicosis reveals two distinct features: whitish, creamy, gelatinous threads known as Demodex tails, and dilated follicular openings containing gray or brown amorphous round plugs, which are surrounded by an erythematous halo, referred to as Demodex follicular openings.^[19]
 15. (c). The most indicative trichoscopic findings of tinea capitis, known for their high predictive value, include comma hairs (51%), corkscrew hairs (32%), Morse code-like hairs (22%), zigzag hairs (21%), bent hairs (27%), block hairs (10%), and i-hairs (10%). In addition, other frequently observed but less characteristic trichoscopic features are broken hairs (57%), black dots (34%), perifollicular scaling (59%), and diffuse scaling (89%).^[20,21]
 16. (d). Morse code-like hairs, zigzag hairs, bent hairs, and diffuse scaling are exclusively found in cases of *Microsporum tinea capitis*, occurring in 28%, 21%, 14%, and 14% of cases, respectively. In contrast, corkscrew hairs are more frequently observed in *Trichophyton tinea capitis*, with a prevalence of 55% compared to 10% in *Microsporum tinea capitis*.^[20,21]
 17. (d). In *Trichophyton tinea capitis*, corkscrew hairs were more commonly detected compared to *Microsporum tinea capitis* (21/38, 55% vs 3/29, 10%).^[20] Given that corkscrew hairs are the main finding in the image, the likely causative organism is *Trichophyton*, so terbinafine should be used for treatment.^[22]
 18. (b). Dermoscopy of pitted keratolysis shows pits and heterogenous architecture at the periphery of craters.^[23]
 19. (d). *Cydnidae* pigmentation is caused by burrowing bugs. Their odorous secretions stain the skin. Dermoscopy shows brown globules and granules, bizarre-shaped pigmented structures, and accentuation of pigmentation along skin furrows and eccrine openings.^[24]
 20. Green nail syndrome and green aurora sign. It is caused by *Pseudomonas aeruginosa* and the greenish discoloration occurs due to pyocyanin pigment. On onychoscopy, 'green aurora' sign is visualized.^[25]
 21. (a). The 'chick-pea flour pattern' in white superficial onychomycosis refers to yellowish-white, opaque, and friable debris on the nail plate, predominantly near the proximal nail fold.^[26]
 22. (d). The primary dermoscopic indicators of onychomycosis include the 'ruin appearance,' 'longitudinal striae,' and 'spikes' located at the proximal edge of onycholytic areas, with specificities of 99.38%, 83.78%, and 85.64%, respectively. The 'aurora borealis' sign demonstrated the greatest sensitivity and

- specificity.^[27]
23. (d). Dendritic pattern is seen in endonyx onychomycosis.^[28]
 24. Aurora borealis sign, seen in distal lateral subungual onychomycosis. Aurora borealis represents areas of various colors ranging from whitish yellow to greenish-blue to bluish-gray to black in onycholytic areas.^[27]
 25. (d). In both hypo- and hyperpigmented variants of pityriasis versicolor, white scales in skin furrows over a dull white or brown background are key dermoscopic characteristics. In addition, perifollicular white scaling, 'contrast halo sign,' a ring of alternating pigmentation around the main lesion, and folliculocentricity are also described.^[29,30]
 26. (c). Yellow or yellowish-orange areas are among the most common dermoscopic findings observed in all subtypes of leprosy, making it a reliable marker for the disease in dermoscopic examinations.^[30,31]
 27. (c). The 'white jade coin pendant sign' in *Talaromyces marneffei* infection is characterized by a circular or nearly circular whitish amorphous structure with a central keratin plug or hemorrhage.^[32,33]
 28. Verruca vulgaris. The dermoscopic characteristics of common warts include brown dots, dotted vessels, and black dots or globules (indicative of thrombosed vessels) against a white background.^[4,30]
 29. (a). Noodle pattern is seen on dermoscopy of crusted scabies due to congregation of multiple burrows at one site.^[34]
 30. 'Halo sign' of herpes zoster. The 'halo sign' results from the contrast between the yellowish-brown crusted center of the vesicular lesions and the red hue of the erythematous background, forming an annular pattern around each vesicle.^[35-37]

Ethical approval

The Institutional Review Board approval is not required.

Declaration of patient consent

The authors certify that they have obtained all appropriate patient consent.

Financial support and sponsorship

Nil.

Conflicts of interest

There are no conflicts of interest.

Use of artificial intelligence (AI)-assisted technology for manuscript preparation

The authors confirm that there was no use of artificial intelligence (AI)-assisted technology for assisting in the

writing or editing of the manuscript and no images were manipulated using AI.

REFERENCES

1. Abraham LS, Azulay-Abulafia L, Aguiar DP, Torres F, Argenziano G. Dermoscopy features for the diagnosis of furuncular myiasis. *An Bras Dermatol* 2011;86:160-2.
2. Criado PR, Landman G, Reis VM, Belda W Jr. Tungiasis under dermoscopy: *In vivo* and *ex vivo* examination of the cutaneous infestation due to *Tunga penetrans*. *An Bras Dermatol* 2013;88:649-51.
3. Gaurav V, Tyagi M, Grover C, Das S. Ungual scabies: A case report and review of literature. *Skin Appendage Disord* 2024;10:60-8.
4. Sonthalia S, Agrawal M, Bhatia J, Zeeshan M, Elsamanoudy S, Tiwary P, *et al*. Entodermoscopy update: A contemporary review on dermoscopy of cutaneous infections and infestations. *Indian Dermatol Online J* 2021;12:220-36.
5. Serarslan G, Ekiz Ö, Özer C, Sarıkaya G. Dermoscopy in the diagnosis of cutaneous leishmaniasis. *Dermatol Pract Concept* 2019;9:111-8.
6. Nirmal B, George R, Kodiatte TA. Dermoscopy of palmar wart with falooda seed appearance. *Australas J Dermatol* 2018;59:155-6.
7. Gaurav V, Agrawal I. Dermoscopy of plantar wart. *CosmoDerma* 2024;4:107.
8. Gaurav V, Agrawal S, Najeeb A, Ahuja R, Saurabh S, Gupta S. Advancements in dermatological imaging modalities. *Indian Dermatol Online J* 2024;15:278-92.
9. Kaliyadan F, Jayasree P, Ashique KT. Ultraviolet reflectance dermoscopy. *Indian J Dermatol Venereol Leprol* 2024. <https://ijdv.com/ultraviolet-reflectance-dermoscopy/>. DOI: 10.25259/IJDVL_1308_2023.
10. González-Ramírez RA, Orendain-Koch N. Hallazgos dermatoscópicos en larva migrans [Dermoscopic findings in cutaneous larva migrans]. *Dermatol Rev Mex* 2015;59:98-101.
11. Zaballos P, Ara M, Puig S, Malveyh J. Dermoscopy of molluscum contagiosum: A useful tool for clinical diagnosis in adulthood. *J Eur Acad Dermatol Venereol* 2006;20:482-3.
12. Gaurav V, Bahadur A. Dermoscopy of molluscum contagiosum with orifice-single lesion in an adult. *CosmoDerma* 2024;4:91.
13. Anand GRP, Gaurav V. Trichobacteriosis pubis presenting as genital bromhidrosis. *Indian Dermatol Online J* 2024. https://journals.lww.com/idoj/fulltext/9900/trichobacteriosis_pubis_presenting_as_genital.208.aspx. DOI: 10.4103/idoj.idoj_580_23 [Last accessed on 2024 July 24].
14. Gaurav V, Modi V, Yadav D. Ultraviolet-induced fluorescence trichoscopy of trichobacteriosis axillaris. *J Skin Sex Transm Dis* 2024. <https://ijdv.com/ultraviolet-reflectance-dermoscopy/>. DOI: 10.25259/JSSTD_21_2024.
15. Ankad BS, Adya KA, Gaikwad SS, Inamadar AC, Manjula R. Lupus vulgaris in darker skin: Dermoscopic and histopathologic incongruity. *Indian Dermatol Online J* 2020;11:948-52.
16. Gaurav V, Grover C, Das S, Rai G. White piedra: An uncommon superficial fungal infection of hair. *Skin Appendage Disord* 2022;8:34-7.

17. Stefani D, Hofmann-Wellenhof A, Zalaudek R. Dermoscopy for diagnosis and treatment monitoring of pediculosis capitis. *J Am Acad Dermatol* 2006;54:909-11.
18. Bhat YJ, Keen A, Hassan I, Latif I, Bashir S. Can dermoscopy serve as a diagnostic tool in dermatophytosis? A pilot study. *Indian Dermatol Online J* 2019;10:530-5.
19. Segal R, Mimouni D, Feuerman H, Pagovitz O, David M. Dermoscopy as a diagnostic tool in demodicidosis. *Int J Dermatol* 2010;49:1018-23.
20. Waškiel-Burnat A, Rakowska A, Sikora M, Ciechanowicz P, Olszewska M, Rudnicka L. Trichoscopy of tinea capitis: A systematic review. *Dermatol Ther (Heidelb)* 2020;10:43-52.
21. Lalmanpuii G, Barman KD, Das S, Gaurav V. Kerion celsi caused by *Trichophyton mentagrophytes*: Clinical, trichoscopic, and microscopic features. *CosmoDerma* 2024;4:70.
22. Tey HL, Tan AS, Chan YC. Meta-analysis of randomized, controlled trials comparing griseofulvin and terbinafine in the treatment of tinea capitis. *J Am Acad Dermatol* 2011;64:663-70.
23. Lockwood LL, Gehrke S, Navarini AA. Dermoscopy of pitted keratolysis. *Case Rep Dermatol* 2010;2:146-8.
24. Poojary S, Baddireddy K. Demystifying the stinking reddish brown stains through the dermoscope: Cydnidae pigmentation. *Indian Dermatol Online J* 2019;10:757-8.
25. Dominguez-Santas M, Diaz-Guimaraens B, Jimenez-Cauhe J, Suarez-Valle A. Dermoscopy of green nail syndrome - The "green aurora sign." *Dermatol Pract Concept* 2021;11:e2021093.
26. Grover C, Jakhar D, Sharma S. The grid pattern of white superficial onychomycosis. *Indian J Dermatol Venereol Leprol* 2020;86:568-70.
27. Litaïem N, Mnif E, Zeglouï F. Dermoscopy of onychomycosis: A systematic review. *Dermatol Pract Concept* 2023;13:e2023072.
28. Jakhar D, Grover C, Kaur I. Dendritic pattern: Unique onychoscopic feature in endonyx. *J Am Acad Dermatol* 2019;81:e89-90.
29. Mathur M, Acharya P, Karki A, Nisha KC, Shah J. Dermoscopic pattern of pityriasis versicolor. *Clin Cosmet Investig Dermatol* 2019;12:303-9.
30. Chauhan P, Behera B, Ding DD, Lallas A, Khare S, Enechukwu, *et al.* Dermoscopy of infectious dermatoses (infectiouscopy) in skin of color-a systematic review by the International Dermoscopy Society "Imaging in Skin of Color" Task Force. *Dermatol Pract Concept* 2023;13(4 S1):e2023309S.
31. Mohta A, Jain SK, Agrawal A, Kushwaha RK, Sharma P, Sethia K, *et al.* Dermoscopy in leprosy: A clinical and histopathological correlation study. *Dermatol Pract Concept* 2021;11:e2021032.
32. Li Q, Wang C, Zeng K, Peng X, Wang F. AIDS-associated disseminated talaromycosis (penicilliosis) marneffeï. *J Dtsch Dermatol Ges* 2018;16:1256-9.
33. Xian J, Huang X, Li Q, Peng X, Peng X. Dermoscopy for the rapid diagnosis of *Talaromyces marneffeï* infection: A case report. *BMC Infect Dis* 2019;19:707.
34. Chavez-Alvarez S, Villarreal-Martinez A, Argenziano G, Ancer-Arellano J, Ocampo-Candiani J. Noodle pattern: A new dermoscopic pattern for crusted scabies (Norwegian scabies). *J Eur Acad Dermatol Venereol* 2018;32:e46-7.
35. Bazzacco G, Conforti C, Toffoli L, Zelin E, Zalaudek I, di Meo N. Dermoscopic features of herpes zoster: Case series and review of the literature. *Dermatol Pract Concept* 2023;13:e2023149.
36. Danish M, Chandra AD, Bhagwat A, Gaurav V. Herpes zoster maxillaris: Clinical, dermoscopic, and microscopic features. *J Skin Sex Transm Dis* 2024. <https://jsstd.org/herpes-zoster-maxillaris-clinical-dermoscopic-and-microscopic-features/>. DOI: 10.25259/JSSTD_19_2024.
37. Gaurav V, Grover C, Sharma S. Acute localised exanthematous pustulosis: A rare cause of localised sterile pustules. *Indian J Dermatol* 2022;67:428-31.

How to cite this article: Gaurav V, Gowda P. Quiz questions from dermoscopy of infectious dermatoses (Infectiouscopy/Entodermoscopy). *J Skin Sex Transm Dis*. doi: 10.25259/JSSTD_32_2024