



Case Report

# Neurocutaneous melanoma in association with giant congenital melanocytic nevi in a child (Touraine syndrome) – A dermatoradiological correlation

Juvaina Puthiyakam<sup>1</sup>, Najeeba Riyaz<sup>2</sup>, Faiz Riyaz Arakkal<sup>3</sup>, Riyaz Arakkal<sup>4</sup>

<sup>1</sup>Department of Radiodiagnosis, Government Medical College, <sup>2</sup>Department of Dermatology, KMCT Medical College, <sup>3</sup>Department of Dermatology, IQRAA Community Hospital Vazhakkau, <sup>4</sup>Department of Paediatrics, KMCT Medical College, Kozhikode, Kerala, India.

**\*Corresponding author:**

Najeeba Riyaz,  
Department of Dermatology,  
KMCT Medical College,  
Kozhikode, Kerala, India.  
najeebaderm@gmail.com

Received : 21 August 2020  
Accepted : 12 September 2020  
Published : 06 April 2021

DOI  
10.25259/JSSTD\_36\_2020

Quick Response Code:



## ABSTRACT

Touraine syndrome or neurocutaneous melanosis/melanoma is a rare melanophakomatosis characterized by extensive/multiple congenital melanocytic nevi associated with cerebral/meningeal melanosis or melanoma. We report a 12-year-old boy with a congenital giant melanocytic nevus on the bathing trunk distribution with scattered lesions on the face, neck, and legs. MRI brain revealed a melanoma in the right amygdala.

**Keywords:** Congenital giant melanocytic nevus, Cerebral melanoma, Touraine syndrome

## INTRODUCTION

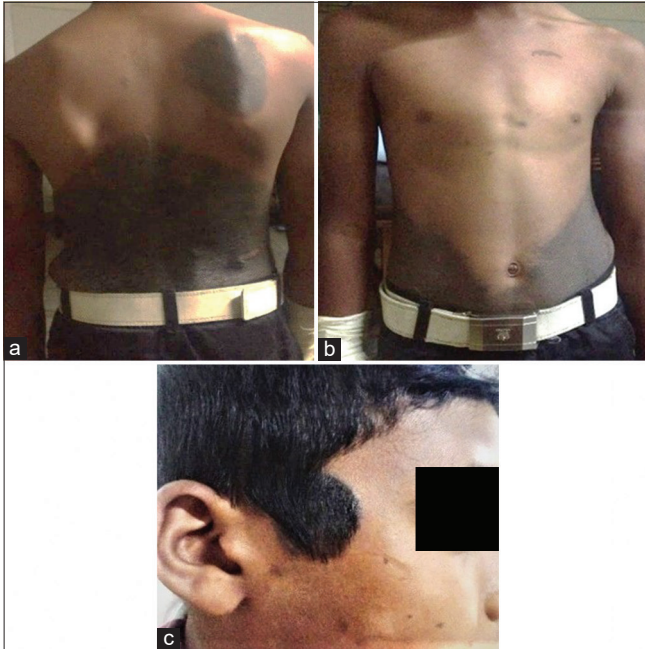Touraine syndrome or neurocutaneous melanosis/melanoma (NCM) is a rare, non-familial, condition described by Rokitansky in 1861.<sup>[1-3]</sup> The diagnostic criteria include multiple (three or more) or large congenital nevi (measuring 9 cm or more on the scalp or 6 cm or more on the body) with melanin-containing cells in the leptomeninges (melanosis or melanoma). Giant congenital melanocytic nevi (GCMN) occur in approximately 1/20,000 of live births.<sup>[1]</sup> The prognosis is bad when neurological manifestations appear. Central nervous system (CNS) involvement is established by MRI.

## CASE REPORT

A 12-year-old boy presented with focal seizures lasting for a few seconds of 2 months duration. He had a large pigmented nevus around the lower trunk since birth. He did not have any neurological deficits. Dermatological examination revealed a giant melanocytic nevus around the lower trunk (size 52 × 30 cm). There were multiple similar smaller circumscribed nevi of size varying from a few millimeters to several centimeters on the right scapular region, anterior chest wall, the right side of the forehead, [Figure 1a-c] left mastoid region, and right leg. MRI brain revealed a curvilinear T1 and T2 hyperintense 20 × 2 mm lesion which was not suppressed in T1-weighted fat-suppressed sequence in the amygdala of the right temporal lobe consistent with brain melanoma [Figure 2a-c].

This is an open-access article distributed under the terms of the Creative Commons Attribution-Non Commercial-Share Alike 4.0 License, which allows others to remix, tweak, and build upon the work non-commercially, as long as the author is credited and the new creations are licensed under the identical terms.

©2021 Published by Scientific Scholar on behalf of Journal of Skin and Sexually Transmitted Diseases



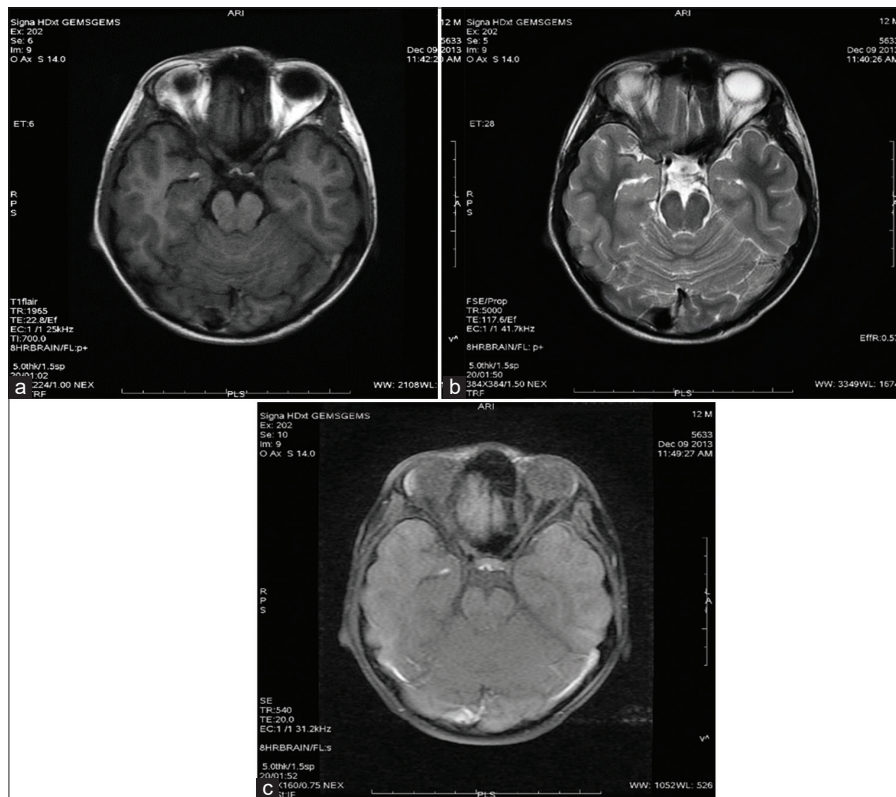
**Figure 1:** (a) Giant melanocytic nevus reaching up to scapulae on the back. Another circumscribed lesion on the (r) scapular region. (b) Melanocytic nevus extending to the lower abdomen and a few small nevi on the anterior chest. (c) A circumscribed melanocytic nevus in the right temporal region.

## DISCUSSION

Neurocutaneous melanosis is characterized by congenital cutaneous nevi (one large nevus or multiple nevi) associated with benign or malignant CNS proliferation of melanocytes.<sup>[1-4]</sup>

The diagnostic criteria, which were first described by Fox and later revised by Kadonaga and Frieden in 1991, include the combination of the following: A single giant congenital nevus (measuring at its greatest diameter  $\geq 20$  cm in adults or  $\geq 9$  cm on the head or  $\geq 6$  cm on the trunk in neonates and infants) or multiple (three or more) congenital nevi, accompanied by meningeal melanosis or CNS melanoma.<sup>[1]</sup> CNS involvement includes parenchymal or leptomeningeal lesions such as melanosis (aggregation of benign melanocytic cells) or melanomas.<sup>[5]</sup> Patients with large cutaneous lesions, particularly over the back, neck, or scalp and multiple (more than three) nevi, have a greater risk for neural involvement.<sup>[6]</sup>

MR imaging findings of NCM show hyperintense T1 signal within the brain parenchyma and leptomeninges due to the paramagnetic effects of stable free radicals within melanin.<sup>[7]</sup> The parenchymal foci are most commonly found in the anterior temporal lobes, specifically the amygdala,



**Figure 2:** (a) Axial T1 W MRI brain showing a curvilinear hyperintense lesion in the right amygdala. (b) Axial T2 W MRI brain showing a curvilinear hyperintense lesion in the right amygdala. (c) Axial T1 fat-suppressed MRI brain showing a curvilinear hyperintense lesion in the right amygdala consistent with cerebral melanoma.

but may also be seen in the cerebellar hemispheres, dentate nuclei, basal ganglia, thalami, and pons.<sup>[8-10]</sup>

## CONCLUSION

Patients with GCMN are at risk for NCM and those with GCMN on the posterior axis or in conjunction with many satellite melanocytic nevi have the greatest risk. The presence of large numbers of satellite nevi is the most important risk factor for NCM in patients with LCMN.

## Declaration of patient consent

The authors certify that they have obtained all appropriate patient consent.

## Financial support and sponsorship

Nil.

## Conflicts of interest

Dr. Najeeba Riyaz is on the editorial board of the Journal.

## REFERENCES

1. Kadonaga JN, Frieden IJ. Neurocutaneous melanosis: Definition and review of the literature. *J Am Acad Dermatol* 1991;24:747-55.
2. Józwiak S, Borkowska J. Neurocutaneous melanosis. In: Ruggieri M, Pascual-Castroviejo I, di Rocco C, editors. *Neurocutaneous Disorders Phakomatoses and Hamartoneoplastic*

- Syndromes. Vienna: Springer; 2008. p. 473-81.
3. Yakut ZL, Bas AY, Turan A, Demirel N, Demirkan TH. Early sonographic diagnosis of neurocutaneous melanosis in a newborn. *Iran J Radiol* 2014;11:e10107.
4. Ramaswamy V, Delaney H, Haque S, Marghoob A, Khakoo Y. Spectrum of central nervous system abnormalities in neurocutaneous melanocytosis. *Dev Med Child Neurol* 2012;54:563-8.
5. Oliveira RS, Carvalho AP, Noro F, Melo AS, Monteiro R, Guimaraes R, *et al.* Neurocutaneous melanosis. *Arq Neuropsiquiatr* 2013;71:130-1.
6. DeDavid M, Orlow SJ, Provost N, Marghoob AA, Rao BK, Wasti Q, *et al.* Neurocutaneous melanosis: Clinical features of large congenital melanocytic nevi in patients with manifest central nervous system melanosis. *J Am Acad Dermatol* 1996;35:529-38.
7. Sealy RC. Radicals in melanin biochemistry. *Methods Enzymol* 1984;105:479-83.
8. Smith AB, Rushing EJ, Smirniotopoulos JG. Pigmented lesions of the central nervous system: Radiologic-pathologic correlation. *Radiographics* 2009;29:1503-24.
9. Demirci A, Kawamura Y, Sze G, Duncan C. MR of parenchymal neurocutaneous melanosis. *AJNR Am J Neuroradiol* 1995;16:603-6.
10. Frieden IJ, Williams ML, Barkovich AJ. Giant congenital melanocytic nevi: Brain magnetic resonance findings in neurologically asymptomatic children. *J Am Acad Dermatol* 1994;31:423-9.

**How to cite this article:** Puthiyakam J, Riyaz N, Arakkal FR, Arakkal R. Neurocutaneous melanoma in association with giant congenital melanocytic nevi in a child (Touraine syndrome) – A dermatoradiological correlation. *J Skin Sex Transm Dis* 2021;3(1):84-6.