



Case Report

Paraneoplastic pemphigus associated with Castleman's disease in a 13-year-old boy

Neema Joy¹, Anuja Elizabeth George², Lissy Skaria³

¹Department of Dermatology, Sagara Co-operative Hospital, Alappuzha, Kerala, India, ²Department of Dermatology, Government Medical College, Thiruvananthapuram, Thiruvananthapuram, Kerala, India, ³Department of Dermatology, Government Medical College, Kottayam, Kerala, India.

***Corresponding author:**

Neema Joy,
Department of Dermatology,
Sagara Co-operative Hospital,
Alappuzha, Alappuzha-688005,
Kerala-India.

drneemajoy@gmail.com

Received : 20 May 2020

Accepted : 02 July 2020

Published : 06 April 2021

DOI

10.25259/JSSTD_22_2020

Quick Response Code:



ABSTRACT

Paraneoplastic pemphigus is an autoimmune blistering disease associated with an underlying malignancy. This is a case of a 13-year-old boy initially presenting with isolated oral erosions – managed as a case of pemphigus, who one and a half years later developed toxic epidermal necrolysis like rash, both refractory to treatment. Evaluation for an underlying malignancy revealed a retroperitoneal Castleman's tumor, following the excision of which there was clinical remission of the oral and skin lesions.

Keywords: Paraneoplastic pemphigus, Paraneoplastic autoimmune multiorgan syndrome, Castleman's disease

INTRODUCTION

Paraneoplastic pemphigus (PNP) is a life-threatening autoimmune blistering disease associated with an underlying malignancy. It was described by Dr. Anhalt in 1990, as an atypical pemphigus associated with neoplasia. In 2001, Nguyen proposed the term paraneoplastic autoimmune multiorgan syndrome (PAMS) because of the recognition that the condition affects multiple organ systems.^[1] It occurs in association with many neoplasms, among which lymphoproliferative diseases are the most common. The clinical presentation of PNP consists typically of painful, severe oral erosions that may be accompanied by a generalized cutaneous eruption and systemic involvement. The cutaneous eruption may be of different morphology, consisting of lesions that resemble pemphigus, pemphigoid, erythema multiforme or graft versus host disease, as well as lesions resembling lichen planus.^[2]

CASE REPORT

A 13-year-old boy, with a history of recent onset breathing difficulty, presented with confluent oral erosions for 4 months without involvement of other mucosae or skin. He had already undergone several courses of treatment with acyclovir because of a positive serological test for HSV (IgM HSV positive), but there was not much improvement. A mucosal biopsy gave a diagnosis of pemphigus vulgaris [Figure 1a and b] and the patient was started on systemic steroids, but on tapering the steroids, he had frequent exacerbations.

He was lost to follow-up for about 1½ years – during which time he was on and off systemic steroids – and came back with exacerbations of the oral lesions along with congestion of

This is an open-access article distributed under the terms of the Creative Commons Attribution-Non Commercial-Share Alike 4.0 License, which allows others to remix, tweak, and build upon the work non-commercially, as long as the author is credited and the new creations are licensed under the identical terms.

©2021 Published by Scientific Scholar on behalf of Journal of Skin and Sexually Transmitted Diseases

eyes and pruritic rashes on the skin. He was on treatment from elsewhere with colchicine (0.5 mg for 1 month) and dapsone (50 mg for 2 months) along with systemic steroid (10 mg prednisolone) before the presentation. On the skin, he had atypical target lesions composed of erythematous macules and plaques with central charring and vesicle, predominantly over face and trunk, affecting 40% of body surface area [Figure 2]. There were also confluent oral erosions and crusting over the lips [Figure 3] as well as conjunctival congestion, with a whitish membrane over conjunctiva, suggestive of membranous conjunctivitis. With a provisional diagnosis of drug-induced toxic epidermal necrolysis, his systemic steroid dosage was increased (6 mg of intravenous betamethasone) but his condition did not improve.

A skin biopsy from a vesicle showed a subepidermal blister with lymphocytes and neutrophils [Figure 4]. Direct immunofluorescence (DIF) from perilesional skin showed intercellular staining with IgG and C3.

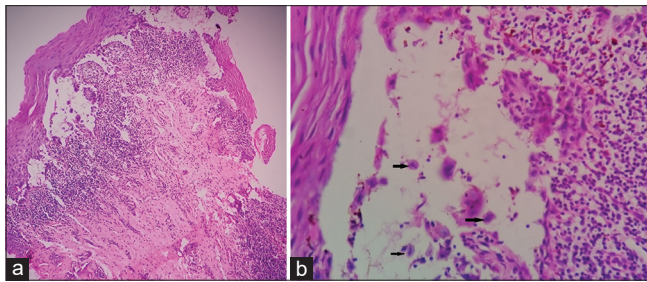


Figure 1: (a) Mucosal biopsy showing large areas of suprabasal separation with acantholytic cells and band-like upper dermal infiltrate of lymphocytes and plasma cells (hematoxylin and eosin, ×100). (b) High-power view of mucosal biopsy showing acantholytic cells in blister cavity (hematoxylin and eosin, ×400).

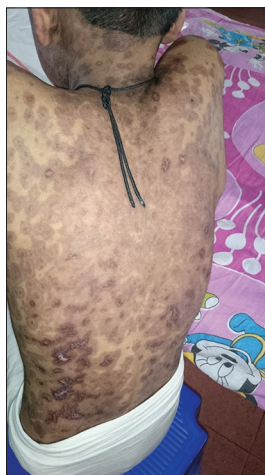

Figure 2: Hyperpigmented and targetoid skin lesions with a few erosions.

Because of the atypical clinical picture and lack of response to steroids, he was investigated further with an ultrasound scan and a CT abdomen. This revealed a mass in the left iliac fossa located extraperitoneally [Figure 5]. It was surgically excised [Figure 6] and the histopathological report was consistent with Castleman's disease [Figure 7]. A final diagnosis of paraneoplastic pemphigus secondary to retroperitoneal Castleman's tumor was made.

Since the boy also had a history of respiratory distress, an X-ray and CT of chest were done which showed only features of small airway disease. There were no features of bronchiolitis obliterans associated with PNP. On follow-up after 2 months of excision, most of his skin lesions had healed and oral erosions were healing. He had recurrent episodes of respiratory distress and was later hospitalized for about 2 months with exacerbation of breathlessness, but his oral, eye, and skin lesions had all remained healed. He expired from severe respiratory failure.

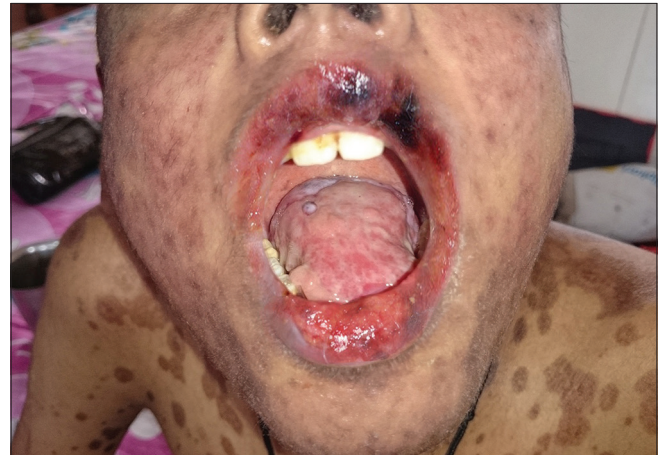

Figure 3: Clinical picture showing erosions of oral mucosa and lips.

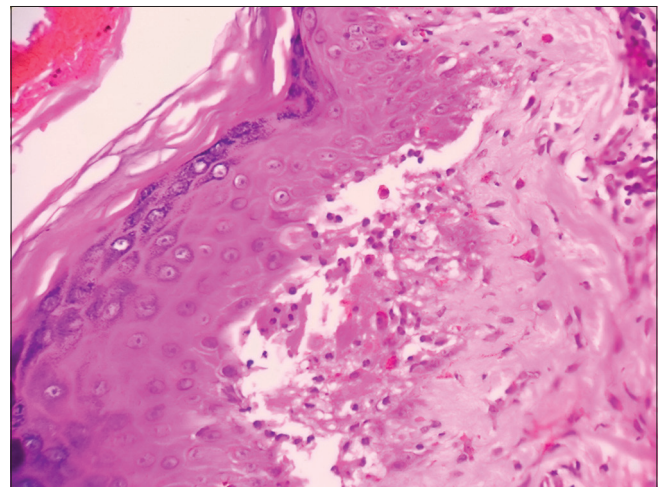


Figure 4: Skin biopsy specimen showing subepidermal blister with lymphocytes (hematoxylin and eosin, ×400).

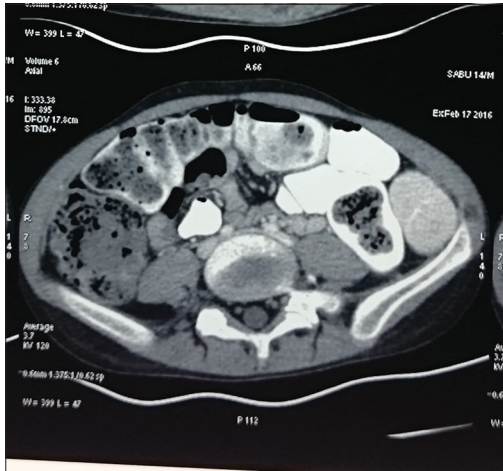


Figure 5: CT scan of abdomen showing tumor in the right iliac fossa, extraperitoneally.

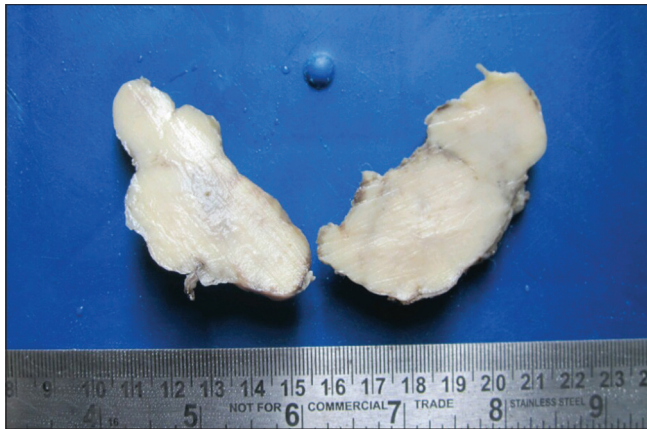

Figure 6: Gross specimen of the resected tumor – fleshy grayish-white mass with faint lobulation on cut section.

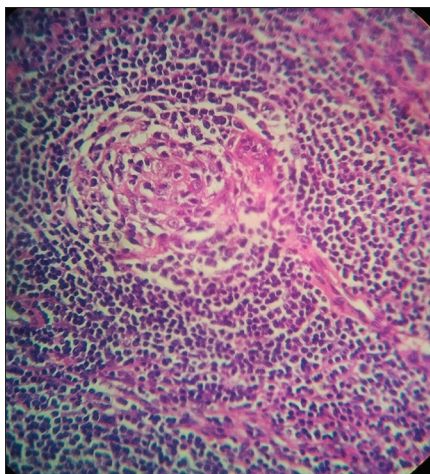


Figure 7: Microscopic section of the tumor showing prominent lymphoid follicles with vascular proliferation and thick hyalinized vessel walls (hematoxylin and eosin, $\times 400$).

DISCUSSION

PNP/PAMS is an autoimmune mucocutaneous vesiculobullous disease associated with specific B-cell lymphoproliferative neoplasms.^[3] The condition presents most frequently between 45 and 70 years of age, but it also occurs in children and adolescents.^[1] Three neoplasms are commonly associated with PNP: Non-Hodgkin's lymphoma (42%), chronic lymphocytic leukemia (29%), and Castleman's disease (10%). Other less common neoplasias described are thymomas (6%), sarcomas (6%), and Waldenstrom's macroglobulinemia. In children, the most common neoplasm associated is Castleman's disease.^[4]

A wide variety of lesions (florid oral mucosal lesions, a generalized polymorphous cutaneous eruption, and pulmonary involvement) may occur in patients with PNP/PAMS. The earliest and most consistent finding is severe oral mucosal erosions. The clinical spectrum consists of at least five different morphological variants. Similarly, histopathological findings of PNP are also very variable.^[1] The histopathological features of PNP correlate with its major clinical variants. The histopathological hallmark of PNP is a predominant interface reaction pattern, characterized by basal cell vacuolar degeneration, dyskeratotic and necrotic keratinocytes, and lymphocytic inflammation characterized by lymphocytic exocytosis with either a sprinkling of lymphocytes at the basement membrane zone (interface vacuolar reaction pattern) or a band-like infiltrate in the upper dermis (interface lichenoid reaction pattern). Intraepidermal blisters with acantholysis may be present but is less prominent than in pemphigus vulgaris. Other less common histopathological features that may be seen include a subepidermal blister, as was observed in our patient. Three distinct staining patterns can be observed on immunofluorescence: (i) Fishnet-like/pemphigus-like intercellular staining, (ii) linear or pemphigoid-like staining at the basement membrane zone, and (iii) homogenous or apoptosis-like staining of the entire cell.^[5] Our patient had an intercellular fishnet-like staining pattern on DIF and IIF.

PNP is characterized by the presence of autoantibodies against antigens such as desmoplakin I (250 kD), bullous pemphigoid antigen I (230 kD), desmoplakin II (210 kD), envoplakin (210 kD), periplakin (190 kD), plectin (500 kD), and a 170 kD protein. Unlike other forms of pemphigus, PNP can affect other types of epithelia, such as gastrointestinal and respiratory tract.^[1] Pulmonary injury with respiratory failure is the cause of death in most cases.^[6]

Castleman's tumors are neoplasms of lymphatic origin, also known as giant lymph node hyperplasia or benign giant lymphoma. Histologically, these tumors can be classified into three types: (a) Hyaline-vascular type (80–90%), (b) plasma cell type (10–20%), and (c) intermediate types. The most

common location of the tumor is the mediastinum (60–70%). Abdominal forms are rare (10–17%), the majority being retroperitoneal. Our patient had a hyaline-vascular variant with retroperitoneal location. Besides the localized forms, multicentric variants with aggressive clinical course, systemic symptoms, organomegaly, and neoplastic transformation have been reported. Castleman's disease has been associated with a very high incidence of autoimmune phenomena such as cytopenia, peripheral neuropathy, systemic lupus erythematosus, Sjogren's syndrome, and myasthenia gravis.^[7] PNP in children and adolescents is most often a presenting sign of occult Castleman's disease, the most common presentation being severe oral mucositis and cutaneous lichenoid lesions.^[3]

Paraneoplastic pemphigus in itself is a rarity and is even more so in children which often causes the condition to be seldom suspected, leading to inadvertent delay in diagnosis. The widely varying clinical picture adds to the confusion and there is every chance of a misdiagnosis. An atypical clinical picture or a poor response to treatment should raise the suspicion of diagnosis and a search for an underlying malignancy can be rewarding and can add the missing piece of the puzzle. Although resection/treatment of the primary neoplasm may lead to remission of the skin and mucosal manifestations, PNP/PAMS is associated with a poor prognosis, especially in cases associated with lung involvement, leading to respiratory failure and death.

Declaration of patient consent

The authors certify that they have obtained all appropriate patient consent.

Financial support and sponsorship

Nil.

Conflicts of interest

Dr. Anuja Elizabeth George is on the editorial board of the Journal.

REFERENCES

1. Wieczorek M, Czernik A. Paraneoplastic pemphigus: A short review. *Clin Cosmet Investig Dermatol* 2016;23:291-5.
2. Yong AA, Tey HL. Paraneoplastic pemphigus. *Australas J Dermatol* 2013;54:241-50.
3. Mimouni D, Anhalt GJ, Lazarova Z, Aho S, Kazerounian S, Kouba DJ, *et al.* Paraneoplastic pemphigus in children and adolescents. *Br J Dermatol* 2002;147:725-32.
4. Porro AM, Lde VC, Lde SM, Enokihara MM. Non-classical forms of pemphigus: Pemphigus herpetiformis, IgA pemphigus, paraneoplastic pemphigus and IgG/IgA pemphigus. *An Bras Dermatol* 2014;89:96-106.
5. Czernick A, Camilleri M, Pittelkow MR, Grando SA. Paraneoplastic autoimmune multiorgan syndrome: 20 years after. *Int J Dermatol* 2011;50:905-14.
6. Nikolskaia OV, Nousari CH, Anhalt GJ. Paraneoplastic pemphigus in association with Castleman's disease. *Br J Dermatol* 2003;149:1143-51.
7. Menenakos C, Braumann C, Hartmann J, Jacobi CA. Retroperitoneal Castleman's tumor and paraneoplastic pemphigus: Report of a case and review of the literature. *World J Surg Oncol* 2007;5:45.

How to cite this article: Joy N, George AE, Skaria L. Paraneoplastic pemphigus associated with Castleman's disease in a 13-year-old boy. *J Skin Sex Transm Dis* 2021;3(1):80-3.