



Letter to Editor

Pachydermodactyly: A case report

Pappinisseri Komalalayam Nikhila¹, Parvathy Santhosh², Kondaramkadavath Nechinathil Jency³, Navya Vanaja Sahadevan⁴

¹CI Cosmetic Clinic, ²Department of Dermatology, Malabar Medical College and Research Centre, ⁴Lisa Skin Clinic, Kozhikode, Kerala, ³Department of Dermatology, SMBT Medical College, Nashik, Maharashtra, India.

***Corresponding author:**

Dr. Pappinisseri Komalalayam
Nikhila,
5131, Bilathikulam Housing
Colony, P.O. Eranhipalam,
Kozhikode, Kerala, India.
nikhila177@gmail.com

Received : 26 April 19
Accepted : 02 May 19
Published : 02 December 19

DOI
10.25259/JSSTD_21_2019

Quick Response Code:



Sir,

Pachydermodactyly is a rare benign digital fibromatosis that manifests clinically as asymptomatic thickening of the skin around proximal interphalangeal joints of fingers, mainly affecting 2nd to 4th digits, without underlying bony or articular changes.^[1] Hyperkeratosis, acanthosis, and increased dermal collagen with a paucity of inflammation are the documented histology features. We report a young adult male who sought medical advice for asymptomatic cutaneous thickening due to pachydermodactyly.

A 21-year-old male presented to our outpatient department with progressive thickening of the skin over the sides of fingers of 3 years duration and no history suggestive of joint involvement such as pain or morning stiffness. The patient had no history of recurrent fever, oral ulcers, photosensitivity, digital tip ulcers, or Raynaud's phenomenon. On further enquiring, the patient admitted that he has a habit of repetitive squeezing of fingers especially while studying or while under stress. Clinical examination revealed symmetrical thickening of the skin over the sides of the proximal aspect of all fingers of both hands, more pronounced over the middle three fingers [Figure 1]. There was no limitation of joint movements. No other body area was similarly affected. No other skin changes were noted anywhere else.

Complete hemogram, erythrocyte sedimentation rate, growth hormone levels, and thyroid function tests were normal. Radiography showed soft tissue widening around proximal phalanges of all fingers with no bony or articular abnormalities [Figure 2]. Ultrasonogram revealed prominent subcutaneous fat. Histopathological examination revealed hyperkeratosis, irregular acanthosis, and mild perivascular inflammation in the papillary dermis [Figure 3a]. Special stain of skin biopsy specimens showed an increase in dermal collagen [Figure 3b] and mucin [Figure 3c]. Considering all these findings, we arrived at a diagnosis of pachydermodactyly. The patient was educated regarding the benign nature of the condition and offered treatment options including intralesional steroid injections and localized resection, which he refused. He was advised to avoid the repetitive squeezing of fingers. The patient was followed up over the telephone after 1 year as he was unable to report personally. He reported a reduction in swelling around his fingers.

The term "pachydermodactyly" is derived from the Greek words pachy (thick), dermo (skin), and dactylos (finger).^[2] It is a benign form of digital fibromatosis characterized by asymptomatic soft tissue swelling affecting the lateral aspects of the proximal interphalangeal joints of the fingers that manifest as noninflammatory bulbous swelling.^[1] First reported by Bazex *et al.* in 1973,^[3] pachydermodactyly usually affects otherwise healthy young individuals with a male predilection.^[4]

This is an open-access article distributed under the terms of the Creative Commons Attribution-Non Commercial-Share Alike 4.0 License, which allows others to remix, tweak, and build upon the work non-commercially, as long as the author is credited and the new creations are licensed under the identical terms.

©2019 Published by Scientific Scholar on behalf of Journal of Skin and Sexually Transmitted Diseases

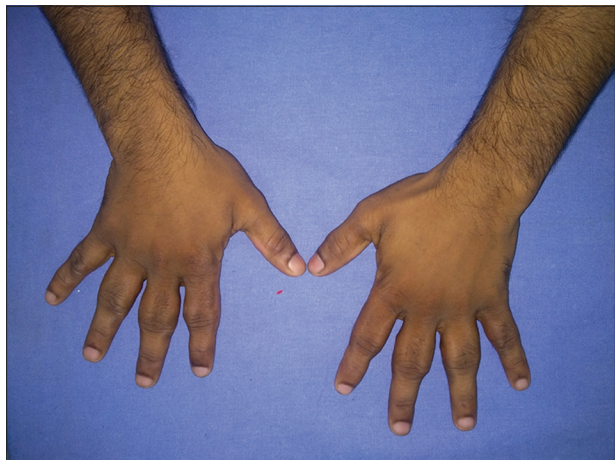


Figure 1: Symmetrical thickening of skin over the sides of proximal aspect of all fingers of both hands, more pronounced over the middle three fingers.

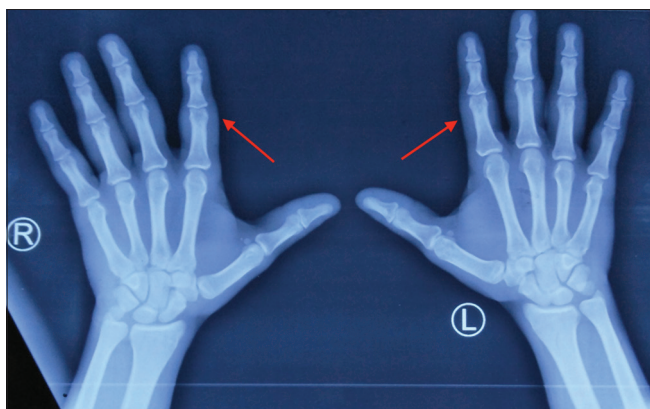


Figure 2: Radiography showing soft tissue widening around proximal phalanges of all fingers with no bony or articular abnormalities.

It presents as bilaterally symmetric involvement of proximal interphalangeal joints of digits II–IV. Underlying bony abnormalities, synovitis, or limitations of joint movement are not reported. Our patient was a 21-year-old male who showed asymptomatic, progressive, and symmetrical involvement around the proximal interphalangeal joints of both hands. The distal interphalangeal joints and other joints are usually not affected. The etiology remains unclear but is attributed to repetitive mechanical skin stimulation by habitual or compulsive interlacing or rubbing of fingers, as observed in our patient.^[2] It may also be seen with occupational exposure, in individuals with Asperger syndrome and with obsessive-compulsive disorder.^[5]

Bardazzi *et al.*^[6] classified PDD into five types: (1) Classic pachydermodactyly, both idiopathic and associated with trauma, primarily described in male patients with several affected fingers (which could be the type in our patient); (2) monopachydermodactyly or localized pachydermodactyly (idiopathic or induced from trauma); (3) pachydermodactyly transgrediens (cutaneous changes extending to palms, particularly to the metacarpophalangeal joints); (4) familial pachydermodactyly (classic or pachydermodactyly transgrediens); and (5) pachydermodactyly associated with tuberous sclerosis.

Investigations including inflammatory markers and serology for antinuclear antibody and rheumatoid factor will be negative, as in our case and helps to differentiate it from common rheumatological conditions that manifest with swelling of digits. Routine imaging studies will only reveal periarticular soft tissue swelling without osteopenia, joint space narrowing, or marginal erosions.^[3] Magnetic resonance imaging findings are fusiform soft tissue swelling around the




Figure 3: (a) Epidermis showing hyperkeratosis, irregular acanthosis, and mild perivascular inflammation in papillary dermis and increased connective tissue in dermis (H&E stain $\times 100$). (b) Increase in dermal collagen (Masson Trichrome stain $\times 100$). (c) Increase in dermal mucin (Alcian blue stain $\times 100$).

proximal interphalangeal joints of the hands with sparing of the tendons and ligaments without capsular involvement or periosteal reaction.^[7]

PDD diagnosis criteria proposed by Chen *et al.*^[11] are as follows: (1) Patient has no symptoms; (2) absent morning stiffness; (3) pain on motion and tenderness to palpation is absent; (4) finger swelling is radial or ulnar in location, rather than circumferential; (5) laboratory investigations are unremarkable; and (6) plain radiographs show only soft tissue swelling, all of which were satisfied by our patient.

The differential diagnoses include thyroid disease, pachydermoperiostosis, acromegaly, knuckle pads, chewing pads, juvenile digital fibromatosis, psoriatic acropachydermodactyly, paraneoplastic acropachydermodactyly, and sarcomas. All arthropathies involving the proximal interphalangeal joints should also be considered, especially juvenile chronic arthritis and juvenile rheumatoid arthritis.^[8,9]

Most patients do not require therapy due to its benign course. Intralesional injection of steroids is a treatment option which provides good results.^[10] Psychological counseling is required for those with compulsive behavior. Surgical excision may be an effective option in selected cases. Our patient refused treatment. He was counseled to refrain from habits producing mechanical skin irritation. Although rare and benign, it is important to recognize and diagnose pachydermodactyly to avoid unnecessary investigations and overenthusiastic interventions.

Declaration of patient consent

The authors certify that they have obtained all appropriate patient consent forms. In the form the patient has given his consent for his images and other clinical information to be reported in the journal. The patient understand that their names and initials will not be published and due efforts will be made to conceal their identity, but anonymity cannot be guaranteed.

Financial support and sponsorship

Nil.

Conflicts of interest

There are no conflicts of interest.

REFERENCES

1. Chen CK, Shyur SD, Chu SH, Huang LH, Kao YH, Liu LC, *et al.* Pachydermodactyly: Three new cases in Taiwan. *J Microbiol Immunol Infect* 2015;48:340-4.
2. Verbov J. Letter: Pachydermodactyly: A variant of the true knuckle pad. *Arch Dermatol* 1975;111:524.
3. Bazex A, Dupr'e A, Teillard J. Pachydermie digitale des premieres phalanges par hyperplasie conjonctive dermique et aplasie hypodermique. *Bull Soc Fr Dermatol Syphiligr* 1973;80:455-8.
4. Beltraminelli H, Itin P. Pachydermodactyly just a sign of emotional distress. *Eur J Dermatol* 2009;19:5-13.
5. Woodrow SL, Burrows NP. Pachydermodactyly in association with asperger syndrome. *Clin Exp Dermatol* 2003;28:674-5.
6. Bardazzi F, Neri I, Raone B, Patrizi A. Pachydermodactyly: Seven new cases. *Ann Dermatol Venereol* 1998;125:247-50.
7. Anandacoomarasamy A, Bak HS, Peduto A, Manolios N. Magnetic resonance imaging in pachydermodactyly. *J Rheumatol* 2005;32:2239-41.
8. Rai A, Zaphiropoulos GC. An unusual case of peri-articular soft tissue finger swelling in an adolescent male: Pachydermodactyly or pachydermoperiostosis? *Br J Rheumatol* 1994;33:677-9.
9. Carpentier KG, Sevenants L, Wouters CH, Morren MA. Pachydermodactyly may mimic juvenile idiopathic arthritis. *Clin Exp Rheumatol* 2005;23:725.
10. Meunier L, Pailler C, Barneon G, Meynadier J. Pachydermodactyly or acquired digital fibromatosis. *Br J Dermatol* 1994;131:744-6.

How to cite this article: Nikhila PK, Santhosh P, Jency KN, Sahadevan NV. Pachydermodactyly: A case report. *J Skin Sex Transm Dis* 2019;1(2):107-9.