

Net Image

# Abrikossoff tumor of the vulva

Pradeep S. Nair<sup>1</sup>, Athira Sudhesan<sup>2</sup>

<sup>1</sup>Department of Dermatology and Venereology, Government Medical College, Trivandrum, Thiruvananthapuram, <sup>2</sup>Department of Dermatology, Government T. D. Medical College Alappuzha, Alappuzha, Kerala, India.

**\*Corresponding author:**

Pradeep S. Nair,  
Department of Dermatology  
and Venereology,  
Government Medical College,  
Thiruvananthapuram, Kerala,  
India.

dvmchtvm@yahoo.co.in

Received: 02 September 2023  
Accepted: 20 September 2023  
Epub Ahead of Print: 25 October 2023  
Published:

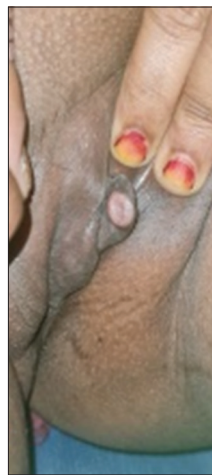DOI  
10.25259/JSSTD\_50\_2023

**Quick Response Code:**



A 36-year-old female patient presented with no history of pre or extramarital sexual contact and gave the history of a single, asymptomatic, and raised lesion over labia minora of 4 years duration. On examination, a single, well defined, non-tender, non-bleeding, oval, reddish brown, and indurated plaque of size 2 × 1 cm with a smooth surface was present at the junction of the upper one-third and lower two-third of left labia minora [Figure 1]. There was no vaginal discharge or inguinal lymphadenopathy. Viral markers for human immunodeficiency virus, hepatitis B, C, and investigations for other sexually transmitted infections were negative.

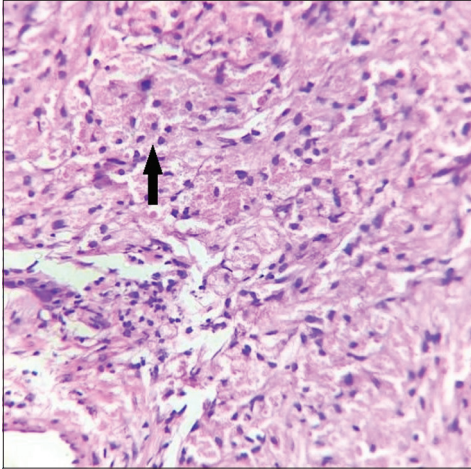
An excision biopsy and histopathological examination demonstrated a tumor composed of sheets of large polyhedral cells with eosinophilic granular cytoplasm and small round central basophilic nuclei with distinct cell borders, diagnostic of Abrikossoff tumor [Figure 2]. Abrikossoff tumor (granular cell tumor) is a rare benign peripheral nerve sheath tumor of Schwann cell origin, the usual sites being the tongue, head, neck, and breast, the vulva being a very rare site. The tumors are S-100 positive and periodic acid-schiff positive, staining the cytoplasmic granules, while diastase resistant. Rarely malignant transformation (2%) may occur. Excision margin is the treatment of choice as this tumor can infiltrate deep and recurrences are possible in 2–8%. In our patient, excision was done with a 1 cm margin of normal skin. Recurrent tumors may



**Figure 1:** Well-defined oval indurated smooth surfaced plaque on left labia minora.

This is an open-access article distributed under the terms of the Creative Commons Attribution-Non Commercial-Share Alike 4.0 License, which allows others to remix, transform, and build upon the work non-commercially, as long as the author is credited and the new creations are licensed under the identical terms.

©2023 Published by Scientific Scholar on behalf of Journal of Skin and Sexually Transmitted Diseases



**Figure 2:** Sheets of well-defined polyhedral cells with granular eosinophilic cytoplasm and central basophilic nuclei (arrow) in the dermis, H & E  $\times 400$ .

be treated with radiation and chemotherapy–pazopanib a selective tyrosine kinase inhibitor that blocks tumor growth and inhibits angiogenesis.

#### **Declaration of patient consent**

The authors certify that they have obtained all appropriate patient consent.

#### **Financial support and sponsorship**

Nil.

#### **Conflicts of interest**

Dr. Pradeep S Nair is on the editorial board of the Journal.

#### **Use of artificial intelligence (AI)-assisted technology for manuscript preparation**

The author(s) confirms that there was no use of artificial intelligence (AI)-assisted technology for assisting in the writing or editing of the manuscript and no images were manipulated using AI.

**How to cite this article:** Nair PS, Sudhesan A. Abrikossoff tumor of the vulva. *J Skin Sex Transm Dis* doi: 10.25259/JSSD\_50\_2023.