

Net Image

Herpes zoster maxillaris: Clinical, dermoscopic, and microscopic features

Mohammad Danish¹, Akash Deep Chandra², Abhishek Bhagwat³, Vishal Gaurav⁴

¹Department of Dermatology and Venereology, Dr. Hedgewar Arogya Sansthan, Delhi, ²Department of Dermatology and Venereology, Kalpana Chawla Government Medical College, Karnal, Haryana, ³Dermatology and Venereology, All India Institute of Medical Sciences, Bilaspur, Himachal Pradesh, ⁴Department of Dermatology and Venereology, Maulana Azad Medical College, New Delhi, India.

***Corresponding author:**

Vishal Gaurav,
Department of Dermatology
and Venereology, Maulana
Azad Medical College,
New Delhi, India.

mevishalgaurav@gmail.com

Received: 26 May 2024
Accepted: 16 June 2024
Epub Ahead of Print: 16 July 2024
Published:

DOI
10.25259/JSSTD_19_2024

Quick Response Code:



A 25-year-old male presented with a painful vesicular eruption on the right side of his face associated with painful erosions in the oral cavity for two days. The mother recalled him having varicella in his childhood years. He did not have any systemic illness or prior similar episodes. Physical examination revealed eroded vesicles on an erythematous base over the right infraorbital area, right nasofacial sulcus, including the tip of the nose, right infranasal area, and right side of the upper lip [Figure 1a]. Examination of oral cavity showed erosions and grouped vesiculopustules on an erythematous base involving the right side of the palate [Figure 1b]. Examination of eye, nasal cavity and ear were unremarkable, except for mild right

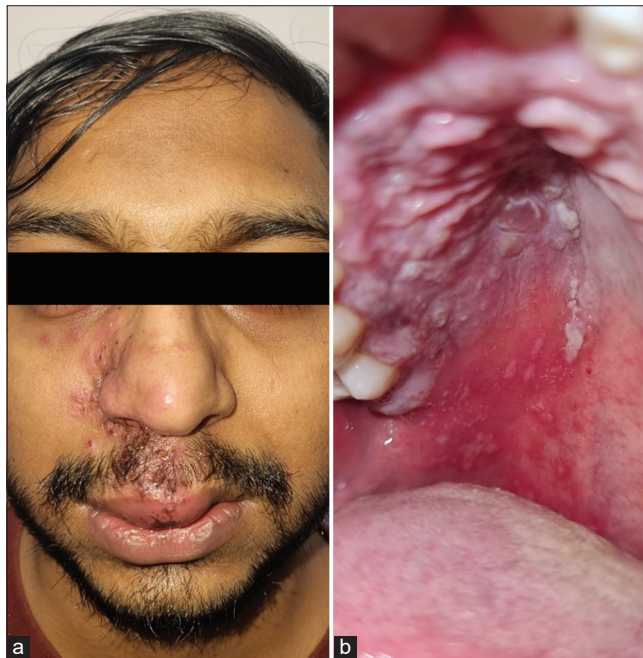

Figure 1: (a) Eroded vesicles on an erythematous base over the right infraorbital area, right nasofacial sulcus, including the tip of the nose, right infranasal area, and right side of the upper lip and (b) Oral cavity showing erosions and grouped vesiculopustules on an erythematous base involving the right half of the palate.

This is an open-access article distributed under the terms of the Creative Commons Attribution-Non Commercial-Share Alike 4.0 License, which allows others to remix, transform, and build upon the work non-commercially, as long as the author is credited and the new creations are licensed under the identical terms.
©2024 Published by Scientific Scholar on behalf of Journal of Skin and Sexually Transmitted Diseases

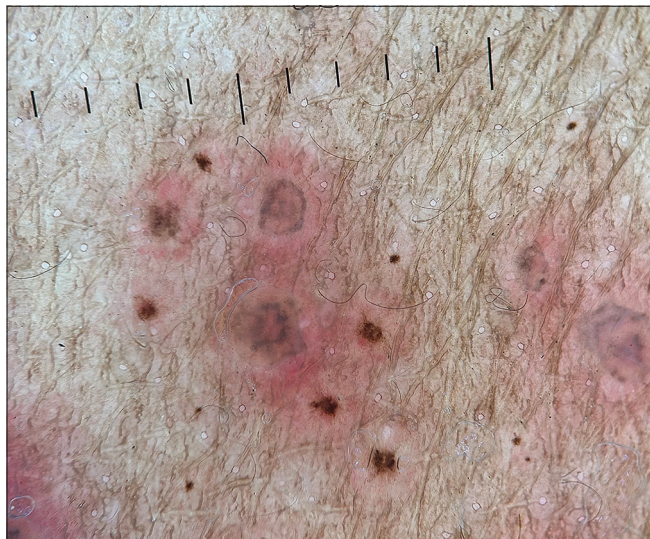

Figure 2: Dermoscopy (Illuco, IDS-1100) showing brownish crusts with polyglobular structures and background erythema (Polarized, $\times 20$).

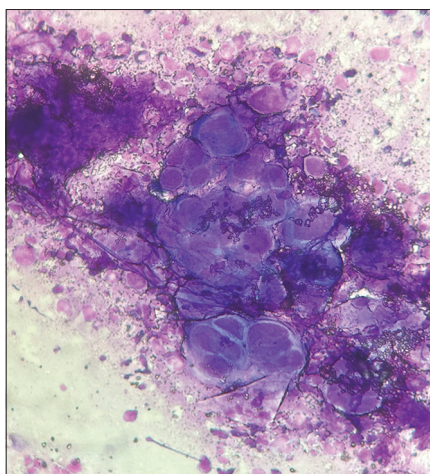


Figure 3: Tzanck smear showing multinucleated giant cells (Giemsa stain $\times 1000$).

lower eyelid edema. Dermoscopy showed brownish crusts with polyglobular structures and background erythema [Figure 2]. Tzanck smear showed many multinucleated giant cells [Figure 3]. The diagnosis of right-sided trigeminal herpes zoster maxillaris was made. He was prescribed oral acyclovir (800 mg 5 times a day) for a week along with diclofenac 50 mg twice daily for pain relief, resulting in complete resolution of the lesions as well as associated symptoms [Figures 4a and b].

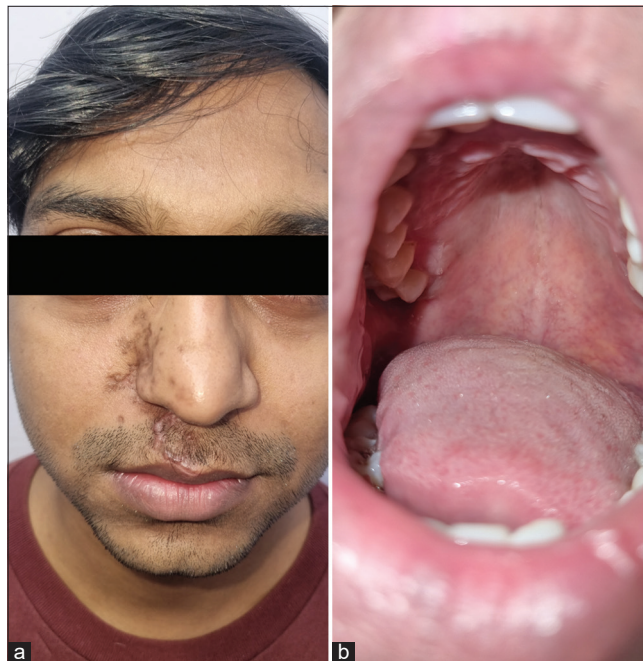

Figure 4: Resolution of (a) Cutaneous and (b) oral lesions following treatment.

Ethical approval

The Institutional Review Board approval is not required.

Declaration of patient consent

The authors certify that they have obtained all appropriate patient consent.

Financial support and sponsorship

Nil.

Conflicts of interest

There are no conflicts of interest.

Use of artificial intelligence (AI)-assisted technology for manuscript preparation

The authors confirm that there was no use of artificial intelligence (AI)-assisted technology for assisting in the writing or editing of the manuscript and no images were manipulated using AI.

How to cite this article: Danish M, Chandra A, Bhagwat A, Gaurav V. Herpes zoster maxillaris: Clinical, dermoscopic, and microscopic features. *J Skin Sex Transm Dis*. doi: 10.25259/JSSSTD_19_2024