

Net Images

The tell-tale strawberry cervix: Clinical insights into trichomoniasis

Munazzah Khan¹, Srishti Dabas¹, Sonika Garg¹

¹Department of Dermatology, Maulana Azad Medical College and Lok Nayak Hospital, New Delhi, India.

***Corresponding author:**

Sonika Garg,
Department of Dermatology,
Maulana Azad Medical College
and Lok Nayak Hospital, New
Delhi, India.

sonikagarg911@gmail.com

Received: 10 January 2025
Accepted: 17 January 2025
Epub Ahead of Print: 04 March 2025
Published:

DOI
10.25259/JSSTD_7_2025

Quick Response Code:



A 29-year-old female presented to the clinic with malodorous vaginal discharge and mild itching for 2 weeks. She reported no dysuria, lower abdominal pain, fever, vaginal bleeding, or dyspareunia. History of unprotected intercourse with a new partner 20 days before the onset of symptoms was present.

Vulval examination revealed grayish white frothy malodorous vaginal discharge, smearing the labia minora [Figure 1]. On per speculum examination, an erythematous cervix with punctate hemorrhagic spots, suggestive of a strawberry cervix, was observed along with frothy discharge [Figure 2]. The discharge pH was 5.2.

Wet mount analysis confirmed flagellated protozoa. Routine tests, pelvic ultrasonography, and human immunodeficiency virus screening were within normal limits. A diagnosis of trichomoniasis was made.

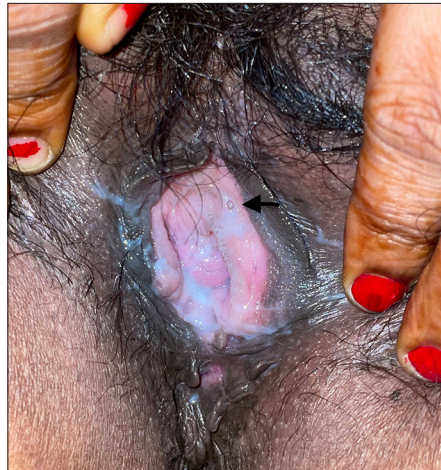

Figure 1: Whitish-to-grayish frothy vaginal discharge (arrow).

This is an open-access article distributed under the terms of the Creative Commons Attribution-Non Commercial-Share Alike 4.0 License, which allows others to remix, transform, and build upon the work non-commercially, as long as the author is credited and the new creations are licensed under the identical terms.

©2025 Published by Scientific Scholar on behalf of Journal of Skin and Sexually Transmitted Diseases

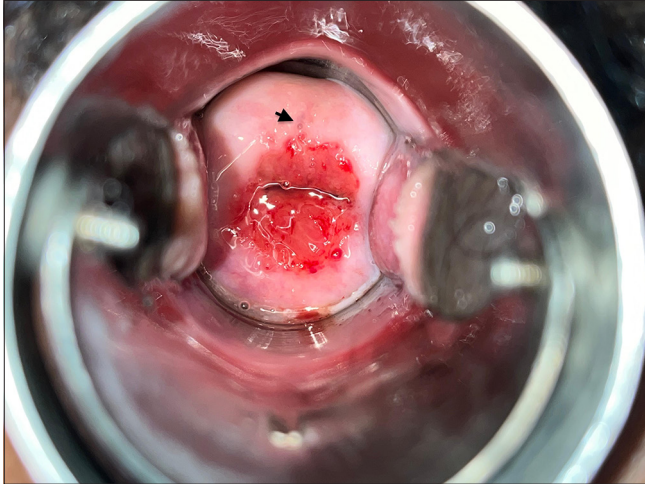


Figure 2: Erythematous cervix with punctate hemorrhagic spots: Strawberry cervix and frothy discharge (arrow).

She and her partner were treated with tablet metronidazole 500 mg orally, twice daily, for 7 days, resulting in significant improvement by the 15-day follow-up.

Ethical approval: Institutional Review Board approval is not required.

Declaration of patient consent: The authors certify that they have obtained all appropriate patient consent.

Financial support and sponsorship: Nil.

Conflicts of interest: There are no conflicts of interest.

Use of artificial intelligence (AI)-assisted technology for manuscript preparation: The authors confirm that there was no use of artificial intelligence (AI)-assisted technology for assisting in the writing or editing of the manuscript and no images were manipulated using AI.

How to cite this article: Khan M, Dabas S, Garg S. The tell-tale strawberry cervix: Clinical insights into trichomoniasis. *J Skin Sex Transm Dis.* doi: 10.25259/JSSTD_7_2025