



Net Case

# Solitary nevus lipomatosus superficialis

Sneha Johny<sup>1</sup>, Sunitha Balakrishnan<sup>2</sup>, Kidangazhiathmana Ajithkumar<sup>1</sup>, Neelakandhan Asokan<sup>1</sup>

Departments of <sup>1</sup>Dermatology, Venereology and Leprology and <sup>2</sup>Pathology, Government Medical College, Thrissur, Kerala, India.

**\*Corresponding author:**

Sneha Johny,  
Department of Dermatology,  
Venereology and Leprology,  
Government Medical College,  
Thrissur, Kerala, India.

snehajohny24@gmail.com

Received : 27 May 2021  
Accepted : 12 June 2021  
EPub Ahead of Print: 19 July 2021  
Published: 14 October 2022

DOI  
10.25259/JSSTD\_48\_2021

Quick Response Code:



## ABSTRACT

Nevus lipomatosus superficialis is a rare form of hamartoma or connective tissue nevus that is characterized by the presence of ectopic adipose tissue within the dermis. They usually present as soft yellowish or skin colored papulonodules with a predilection for the buttocks, upper thigh, and lumbar back. We report a solitary form of nevus lipomatosus superficialis in a 63-year-old woman who presented with a skin colored pedunculated mass. Histopathology showed mature adipocytes in lobules extending to the papillary dermis.

**Keywords:** Nevus lipomatosus superficialis, Connective tissue nevus, Hamartoma

## INTRODUCTION

Nevus lipomatosus superficialis is a rare form of hamartoma or connective tissue nevus that presents with soft, yellowish or skin colored papulonodules with a predilection for the buttocks, upper thigh, and lumbar back. It was first described in 1921 by Hoffmann and Zurhelle.<sup>[1,2]</sup> Two clinical types are described: The multiple form (classical type) and solitary form. Histology is characteristic with ectopic, mature adipose tissue in the reticular and papillary dermis.<sup>[1,3]</sup> We report a case of this rare cutaneous malformation in its solitary form.

## CASE REPORT

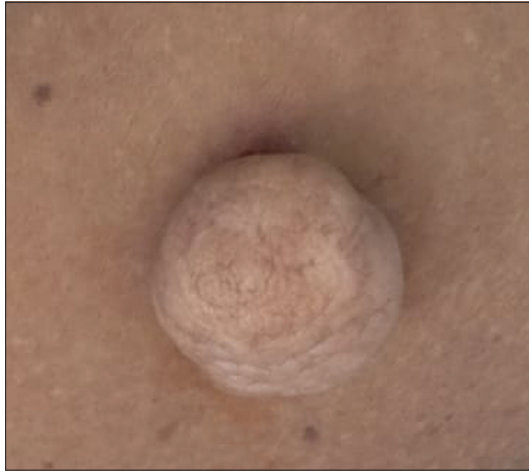A 63-year-old female presented with single asymptomatic mass on the right thigh for 6 years. There was no history of recent or rapid increase in size, pain, or bleeding. Her medical history was uneventful. There was no history of similar illness in the family.

Cutaneous examination revealed a single, skin colored, soft, pedunculated mass of size 3 × 3 cm on the medial aspect of the right thigh. Skin overlying the lesion was cerebriform with no other surface changes [Figure 1]. There were no other significant skin lesions. Systemic examination was normal. The differential diagnoses were pedunculated neurofibroma and skin tag. Patient underwent excision biopsy of the lesion.

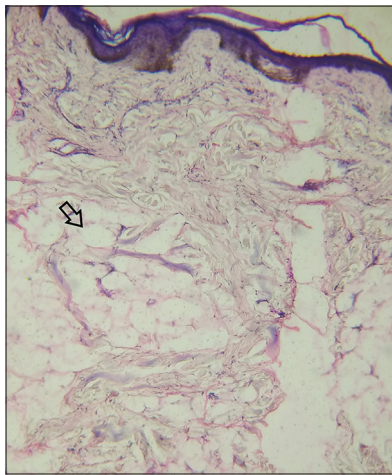
Histopathological examination showed epidermal thinning. Adipose tissue, interspersed among the collagen bundles occupied most of the dermis, confirming a diagnosis of nevus lipomatosus superficialis [Figure 2].

This is an open-access article distributed under the terms of the Creative Commons Attribution-Non Commercial-Share Alike 4.0 License, which allows others to remix, tweak, and build upon the work non-commercially, as long as the author is credited and the new creations are licensed under the identical terms.

©2021 Published by Scientific Scholar on behalf of Journal of Skin and Sexually Transmitted Diseases



**Figure 1:** Skin colored soft, pedunculated mass of solitary nevus lipomatosus superficialis.



**Figure 2:** Section of skin from lesion of solitary nevus lipomatosus superficialis showing focal epidermal thinning and mature adipocytes arranged in lobules (black arrow) reaching into the papillary dermis (H and E, 100×).

## DISCUSSION

Nevus lipomatosus superficialis is an uncommon, idiopathic, benign, hamartomatous anomaly of the skin. Classical lesions are multiple, soft, skin colored, or yellowish papules coalescing into plaques. They are pedunculated, non-tender, and cerebriform lesions which are usually located on pelvic girdle area, gluteal region, and thighs. They occur at birth or during the first three decades of life.<sup>[1,3]</sup>

Solitary lesions usually occur during third to sixth decades of life, much later than the classical form. They present as single sessile or pedunculated nodule with no particular predilection for sites.<sup>[3]</sup>

The exact etiopathogenesis is not known. Certain theories have been proposed to explain the heterotopic occurrence

of adipose tissues which include mesenchymal perivascular differentiation of lipoblasts, and adipose metaplasia in dermal connective tissue. Deletion affecting chromosome 2 (2p24) has also been described.<sup>[4]</sup>

Clinical differential diagnosis includes plexiform neurofibroma, skin tag, fibroepithelial polyp, lymphangioma, and leiomyoma cutis. These can be distinguished histopathologically.<sup>[5]</sup> Histological features of nevus lipomatosus superficialis are groups and strands of fat cells interspersed among collagen bundles within the dermis. The proportion of adipose tissue varies greatly from <10 % of the dermis to more than 50%.<sup>[3]</sup>

Treatment is usually for cosmetic reasons and a surgical excision is curative. Carbon dioxide laser is also found useful.<sup>[6]</sup> Recurrences after surgery are uncommon. Systemic complications and malignant transformation have not been reported so far.

## CONCLUSION

We report a 63-year-old woman who presented with single, asymptomatic, skin colored, pedunculated mass on the right thigh. The excision biopsy showed the presence of adipose tissue interspersed among collagen bundles in the dermis which is characteristic of nevus lipomatosus superficialis. Nevus lipomatosus superficialis is a rare form of hamartoma or connective tissue nevus and the solitary type is still rarer.

## Declaration of patient consent

Patient's consent not required as patients identity is not disclosed or compromised.

## Financial support and sponsorship

Nil.

## Conflicts of interest

Dr. Kidangazhiathmana Ajithkumar and Dr. Neelakandhan Asokan are on the editorial board of the Journal.

## REFERENCES

1. Jain A, Sharma A, Sharda R, Aggarwal C. Nevus lipomatosus cutaneous superficialis: A rare hamartoma. *Indian J Surg Oncol* 2020;11:147-9.
2. Hoffman E, Zurhelle E. Ubre einen naevus lipomatosus cutaneous superficialis der linken glutaalgegend. *Arch Dermatol* 1921;150:327-33.
3. Dhamija A, Mehedra A, D'Souza P, Meena RS. Nevus lipomatosus cutaneous superficialis: An unusual presentation. *Indian Dermatol Online J* 2012;3:196-98.
4. Leung AK, Barankin B. Nevus lipomatosus superficialis on the left proximal arm. *Case Dermatol Med* 2017;10:1155.
5. Bhushan P, Thatte SS, Sing A. Nevus lipomatosus cutaneous

- superficialis: A report of two cases. Indian J Dermatol 2016;61:123.
6. Sardana K, Bansal S, Garg VK, Khurana N. Treatment of nevus lipomatosus cutaneous superficialis with CO<sub>2</sub> laser. J Cosmet Dermat 2017;16:333-5.

**How to cite this article:** Johny S, Balakrishnan S, Ajithkumar K, Asokan N. Solitary nevus lipomatosus superficialis. J Skin Sex Transm Dis 2022;4:254-6.