

Net Images

Accessory nail of the right index finger following trauma

Senkadhir Vendhan¹, Sushmita Mishra², Rajesh Kumar Godugula¹

¹Department of Dermatology, Southern Railway Headquarters Hospital, Chennai, Tamil Nadu, ²Department of Dermatology, Armed Forces Medical College, Pune, Maharashtra, India.

*Corresponding author:

Senkadhir Vendhan,
Department of Dermatology,
Southern Railway Headquarters
Hospital, Chennai, Tamil Nadu,
India.

vendhan100@gmail.com

Received: 26 November 2025

Accepted: 12 January 2026

Epub Ahead of Print: 26 March 2026

Published:

DOI

10.25259/JSSTD_186_2025

Quick Response Code:



A 35-year-old man presented with a hard, curved, nail-like projection arising adjacent to the right ring-finger nail for 1 year. The lesion was asymptomatic. He reported a history of trauma to the same finger 2 years earlier. Examination revealed a separate, well-defined, translucent keratin plate distal to the proximal nail fold, distinct from the main nail [Figure 1]. Dermoscopy was performed using contact polarized (10x) mode with a liquid interface, which demonstrated parallel longitudinal striations with a smooth, shiny surface, and absence of vascular or hemorrhagic structures, consistent with an accessory (ectopic) nail [Figure 2]. The patient was counseled regarding the benign nature of the lesion. Surgical excision was advised; however, he opted for conservative management as the lesion was asymptomatic.

Ectopic nail (onychoheterotopia) is a rare entity, with fewer than 100 cases reported in the literature.^[1] It may be congenital or acquired following traumatic implantation of nail matrix cells. Surgical excision of the ectopic matrix is the definitive treatment.^[2] Recognition of this benign condition prevents misdiagnosis as onychomatricoma or cutaneous horn.

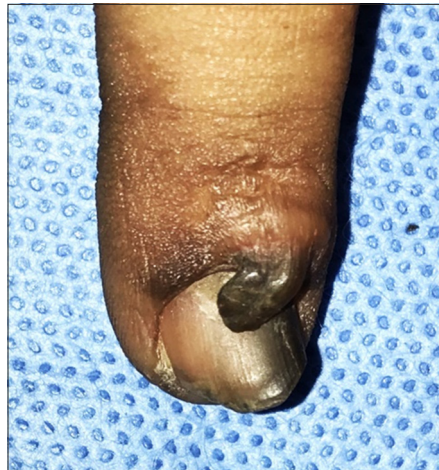

Figure 1: Clinical image showing a separate, curved, nail-like keratin plate adjacent to the right index fingernail.

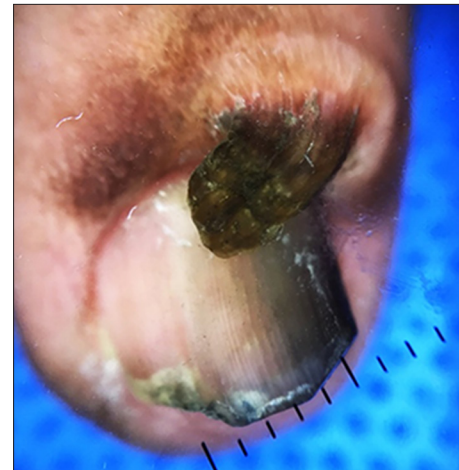


Figure 2: Parallel longitudinal ridges and a smooth, shiny nail-like surface without vascular structures. (Dermalite, contact polarized, 10x).

This is an open-access article distributed under the terms of the Creative Commons Attribution-Non Commercial-Share Alike 4.0 License, which allows others to remix, transform, and build upon the work non-commercially, as long as the author is credited and the new creations are licensed under the identical terms.

©2026 Published by Scientific Scholar on behalf of Journal of Skin and Sexually Transmitted Diseases

Ethical approval: Institutional Review Board approval is not required.

Declaration of patient consent: The authors certify that they have obtained all appropriate patient consent forms. In the form, the patients have given their consent for their images and other clinical information to be reported in the journal. The patients understand that their names and initials will not be published and due efforts will be made to conceal their identity, but anonymity cannot be guaranteed.

Financial support and sponsorship: Nil.

Conflicts of interest: There are no conflicts of interest.

Use of artificial intelligence (AI)-assisted technology for manuscript preparation: The authors confirm that there was no use of artificial intelligence (AI)-assisted technology for assisting

in the writing or editing of the manuscript, and no images were manipulated using AI.

REFERENCES

1. Hwang SM, Cho KH, Kim HD, Jung YH, Kim HI. Posttraumatic ectopic nail. *Arch Plast Surg* 2013;40:793-4.
2. Chatterjee K, Chaudhuri A, Chatterjee G. Onychoheterotopia: A unique case. *Indian J Dermatol* 2013;58:150-1.

How to cite this article: Vendhan S, Mishra S, Godugula R. Accessory nail of the right index finger following trauma. *J Skin Sex Transm Dis*. doi: 10.25259/JSSD_186_2025